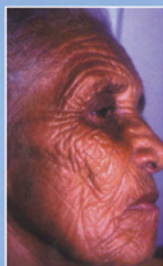
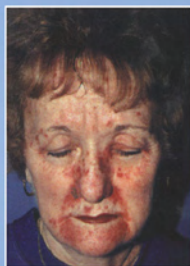
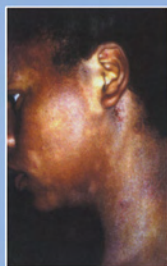Atlas of  
**WOMEN'S  
DERMATOLOGY**

From Infancy to Maturity



Taylor & Francis  
Taylor & Francis Group

Lawrence Charles Parish • Sarah Brenner  
Marcia Ramos-e-Silva • Jennifer L Parish

**Also available as a printed book  
see title verso for ISBN details**

# Atlas of WOMEN'S DERMATOLOGY

From Infancy to Maturity

# Atlas of **WOMEN'S** **DERMATOLOGY**

**From Infancy to Maturity**

Lawrence Charles Parish, MD

Clinical Professor of Dermatology and Cutaneous Biology; and  
Director of the Jefferson Center for International Dermatology  
Jefferson Medical College of Thomas Jefferson University Philadelphia; and  
Visiting Professor of Dermatology  
Tulane University School of Medicine, New Orleans, USA

Sarah Brenner, MD

Head, Department of Dermatology Tel Aviv Sourasky Medical Center,  
Ichilov Hospital; and Clinical Associate Professor of Dermatology,  
Sackler School of Medicine, Tel Aviv University Tel Aviv, Israel

Marcia Ramos-e-Silva, MD PhD

Head, Sector of Dermatology Associate Professor of Dermatology,  
School of Medicine and HUCFF  
Universidade Federal de Rio de Janeiro, Rio de Janeiro, Brazil

Jennifer L Parish, MD

Assistant Clinical Professor of Dermatology and Cutaneous Biology,  
Jefferson Medical College of Thomas Jefferson University, Philadelphia; and  
Assistant Professor of Dermatology,  
Tulane University School of Medicine, New Orleans, USA



**Taylor & Francis**  
Taylor & Francis Group

LONDON AND NEW YORK

© 2006 Taylor & Francis, an imprint of the Taylor & Francis Group

First published in the United Kingdom in 2006 by Taylor & Francis, an imprint of the Taylor & Francis Group, 2 Park Square, Milton Park Abingdon, Oxon OX14 4RN, UK

Tel: +44 (0) 20 7017 6000

Fax.: +44 (0) 20 7017 6699

Email: [info.medicine@tandf.co.uk](mailto:info.medicine@tandf.co.uk)

Website: <http://www.tandf.co.uk/medicine>

This edition published in the Taylor & Francis e-Library, 2006.

“To purchase your own copy of this or any of Taylor & Francis or Routledge’s collection of thousands of eBooks please go to <http://www.ebookstore.tandf.co.uk/>.”

All rights reserved. No part of this publication may be reproduced, stored in a retrieval system, or transmitted, in any form or by any means, electronic, mechanical, photocopying, recording, or otherwise, without the prior permission of the publisher or in accordance with the provisions of the

Copyright, Designs and Patents Act 1988 or under the terms of any licence permitting limited copying issued by the Copyright Licensing Agency, 90 Tottenham Court Road, London W1P 0LP.

Although every effort has been made to ensure that all owners of copyright material have been acknowledged in this publication, we would be glad to acknowledge in subsequent reprints or editions any omissions brought to our attention.

British Library Cataloguing in Publication Data

Data available on application

Library of Congress Cataloging-in-Publication Data

Data available on application

ISBN 0-203-49187-4 Master e-book ISBN

ISBN 0-203-62373-8 (OEB Format)

ISBN10 1-84214-208-9 (Print Edition)

ISBN13 9-78-1-84214-208-0 (Print Edition)

Distributed in North and South America by

Taylor & Francis 2000 NW Corporate Blvd Boca Raton, FL 33431, USA

*Within Continental USA*

Tel: 800 272 7737; Fax.: 800 374 3401

*Outside Continental USA*

Tel: 561 994 0555; Fax.: 561 361 6018

E-mail: [orders@crcpress.com](mailto:orders@crcpress.com)

Distributed in the rest of the world by Thomson Publishing Services Cheriton House North Way

Andover, Hampshire SP10 5BE, UK

Tel: +44 (0) 1264 332424

E-mail: [salesorder.tandf@thomsonpublishingservices.co.uk](mailto:salesorder.tandf@thomsonpublishingservices.co.uk)

Composition by Parthenon Publishing

# Contents

Preface	vii
Dermatology Lexicon Project	x

## **DISEASES OF INFANTS AND CHILDREN INCLUDING HEREDITARY DISEASES**

1. Diseases of newborns	3
2. Diseases of young girls	14
3. Genodermatoses	21

## **DISEASES OF SKIN STRUCTURE—NON-HEREDITARY**

4. Disorders of the sebaceous, apocrine, and eccrine glands	31
5. Disorders of the nails	37
6. Disorders of the hair and the scalp	43

## **OTHER DISEASES**

7. Papulosquamous diseases	55
8. Diseases of pigment changes	74
9. Vesicular and bullous diseases	82
10. Connective tissue diseases	92
11. Vascular diseases	100
12. Cutaneous tumors	108
13. Cutaneous manifestations of systemic diseases	130

14. Drug eruptions	136
15. Psychodermatology	142

## **INFECTIONS AND INFESTATIONS**

16. Bacterial and mycobacterial diseases	150
17. Rickettsial diseases	162
18. Viral diseases	164
19. Superficial and deep fungal diseases	170
20. Parasitic diseases	182
21. Sexually transmitted disease and AIDS	189

## **TOPOGRAPHIC DERMATOLOGY**

22. Diseases of the breast	203
23. Oral lesions	211
24. Perineal and perianal diseases	219
25. Diseases of the vulva	222

## **DISEASES AND CONDITIONS OF PREGNANCY**

26. Pregnancy-related diseases and conditions	232
Index	239

## Preface

This color *Atlas of Women's Dermatology* has been conceived to complement our book, *Women's Dermatology: From Infancy to Maturity*<sup>1</sup>. Although that text was illustrated with some color photography, we wanted the opportunity to provide additional pictures of skin diseases afflicting girls and women.

The word 'atlas' originally referred to the Greek god who held up 'the pillars of the universe'. In medical publishing, it has come to mean a collection of illustrations, designed with the concept that one picture is worth a thousand words<sup>2</sup>. With the development of the Kodachrome<sup>TM</sup>, also termed slides or diazopositives, enormous collections of dermatologic pictures were amassed, now augmented and even replaced with the advent of digital photography.

How then could our photographic story be told? In a previous atlas, one of the authors (LCP) utilized a morphologic format, so that diseases with manifestations on the scalp might be in that chapter and those of the leg in a separate grouping<sup>3</sup>. Two other atlases were organized according to disease classifications<sup>4,5</sup>. These three atlases also contained descriptive introductions so that the pictures would be better defined. We considered these choices but decided upon a simpler presentation with the pictures being labeled according to the illustrated skin disease and the sections being organized in the manner of the textbook chapters, where possible.

Pictures have been selected to present skin diseases in girls and women. Whereas the textbook focused on discussion of conditions that are more prevalent or different in the distaff population, we have included entities that may appear in both sexes but which we thought would be useful to illustrate. By no means should this Atlas be considered all inclusive. Some diseases may not be illustrated at all, while others might require several pictures to complete the story.

We are most appreciative of the many colleagues who have permitted us to borrow from their collections. We are also grateful to our patients who permitted their diseases to be photographed and to whom we express our thanks.

## REFERENCES

1. Parish LC, Brenner S, Ramos-e-Silva M. *Women's dermatology: from infancy to maturity* New York: Parthenon Publishing, 2001.
2. Kuner N, Hartschuh W. Possibilities and limits of early photography in dermatology. The 'Clinique photographique de l'hopital Saint-Louis' von 1868. *Hautarzt* 2003; 54:760-4.
3. Parish LC, Kauh YC, Luscombe HA. *Color atlas of difficult diagnoses in dermatology*. New York: Igaku-Shoin, 1993:1-144.

4. Parish LC, Witkowski JA, Vassileva S. Color atlas of cutaneous infections. Cambridge, MA: Blackwell Scientific, 1995:1–176.
5. Parish LC, Sehgal VN, Buntin DM. Color atlas of sexually transmitted diseases. New York: Igaku-Shoin, 1991:1–173.



# Dermatology Lexicon Project

As a medical specialty, dermatology has the unique semantic history of overlapping and confusing diagnostic terms, eponyms, and synonyms, sometimes resulting in poor or mistaken communication and teaching. In addition, the current digital transformation of healthcare documentation and communication may even accentuate problems with terminology, rather than improve them.

In 2001, the National Institute of Arthritis and Musculoskeletal and Skin Diseases (NIAMS), National Institute of Health (NIH) National Institute of Arthritis, and the Carl J Herzog Foundation sponsored the initial development of the Dermatology Lexicon Project (DLP). Centered at the University of Rochester, the DLP has become an ongoing nationally collaborative effort of dermatologists to develop a well organized, consistent, and accurate terminology for our specialty.

The *Atlas of Women's Dermatology: From Infancy to Maturity* is the first publication to display DLP diagnostic code identifiers. The value of these codes lies not within the unique number associated with a diagnosis, but within a greater network of meaning. The codes seen in this Atlas are a subset of a much larger, detailed map of dermatologic words. Such a semantic map or classification of words strives to be a wide angled, detailed view of all of the diagnostic concepts used in the field of dermatology.

Each diagnosis in this book has a unique code. While each code represents a single diagnostic concept, a specific concept can have multiple clinical findings but only ONE meaning. The relationship between diagnoses seen within this text and other dermatologic diagnoses can be easily reviewed by searching the diagnostic term database at <http://www.dermatologylexicon.org/>

**Art Papier, MD**

Associate Professor of Dermatology  
University of Rochester School of  
Medicine and Dentistry  
Rochester, New York, USA

**Lowell A Goldsmith, MD MPH**

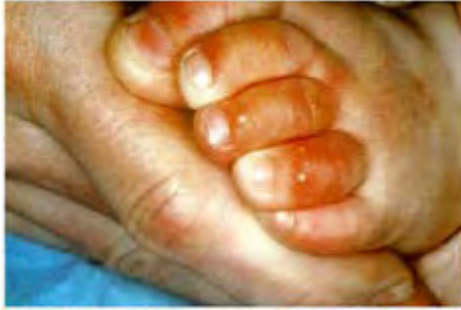Professor of Dermatology  
University of North Carolina School of Medicine  
Chapel Hill, North Carolina, USA

*This project has been funded in whole or in part with Federal funds from the National Institute of Arthritis and Musculoskeletal and Skin Diseases, National Institute of Health, Department of Health and Human Services, and with funds from the Carl J Herzog Foundation, Inc. under contract no. NO1-AR-1-2255.*

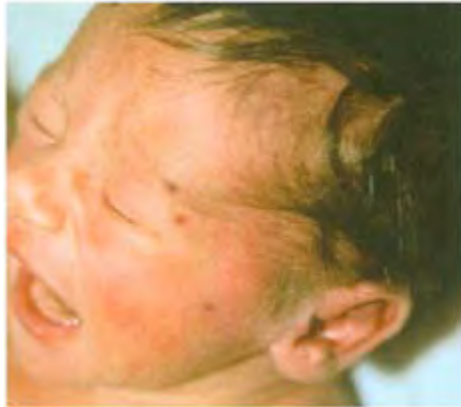Diseases of infants and  
children including hereditary  
diseases

# 1

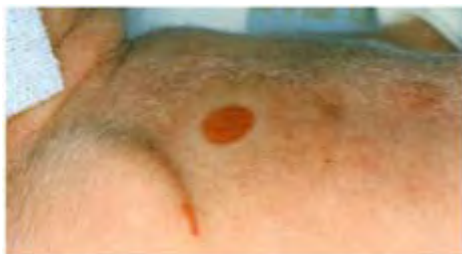## Diseases of newborns



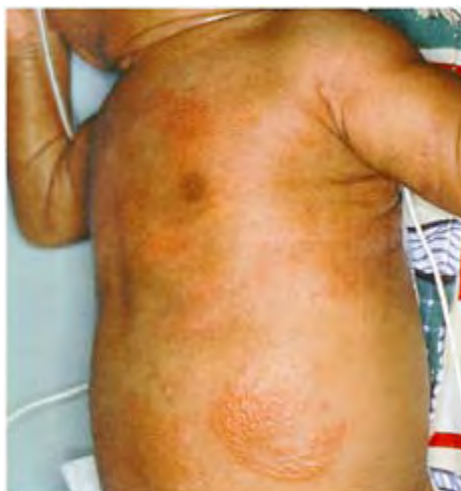**Figure 1.1** Acropustulosis, infantile. Dermatology Lexicon Project (DLP) preferred term and number: *acropustulosis of infancy 2049*. Courtesy of Dr D Wallach, Paris, France



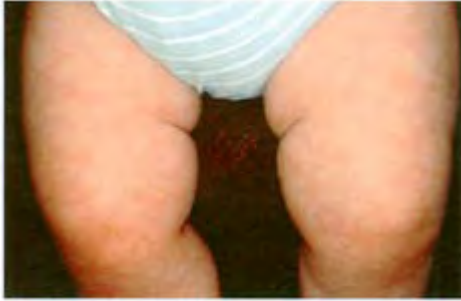**Figure 1.2** Blueberry muffin syndrome. DLP ID: *congenital cytomegalovirus infection 525*. Courtesy of Drs D Wallach and O Enjoiras, Paris, France



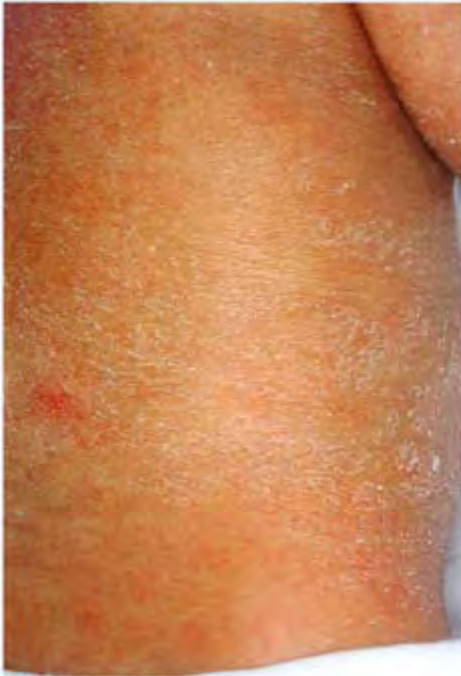**Figure 1.3** Burn, first degree due to  $pO_2/pCO_2$  monitor. DLP ID: *first-degree burn 4045*. Courtesy of Dr D Wallach, Paris, France



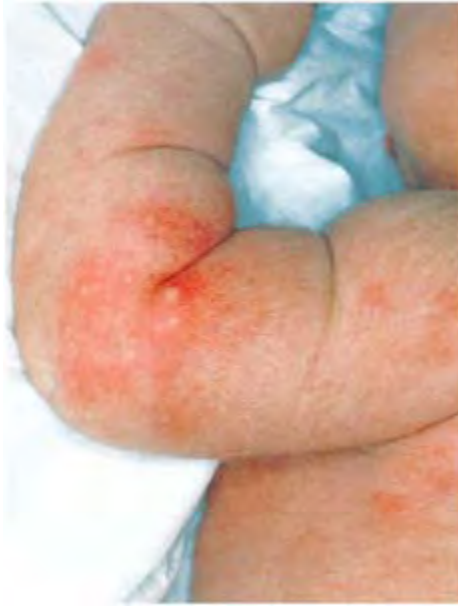**Figure 1.4** Contact dermatitis due to cardiorescope probes. DLP ID: *irritant contact dermatitis 2102*. Courtesy of Dr D Wallach, Paris, France



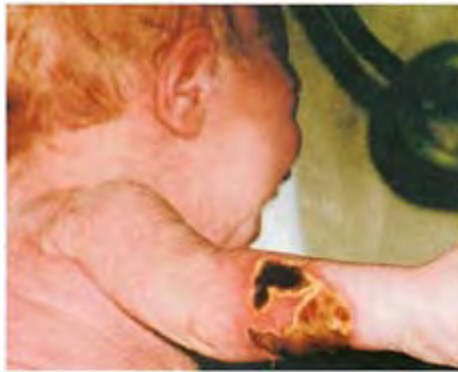**Figure 1.5** Cutis marmorata. DLP ID: *cutis marmorata 2444*. Courtesy of Dr D Wallach, Paris, France



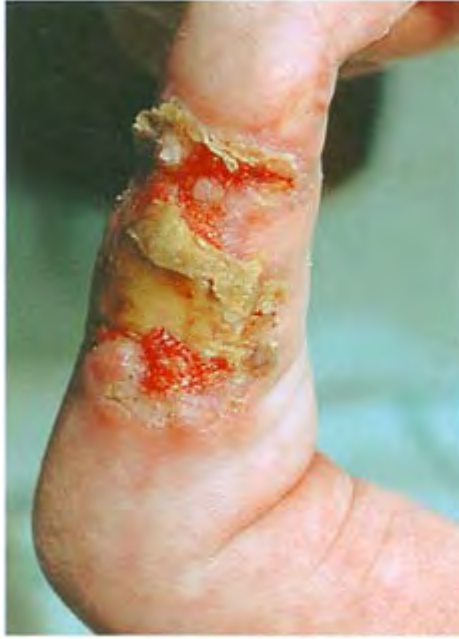**Figure 1.6** Desquamation, physiologic. DLP ID: *desquamation 4983*. Courtesy of Dr D Wallach, Paris, France



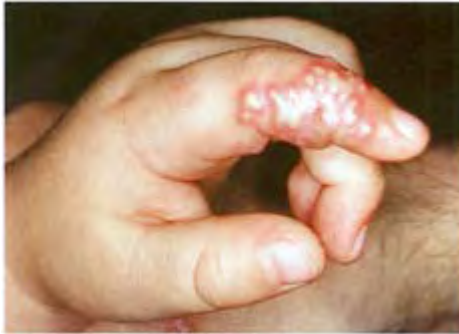**Figure 1.7** Erythema toxicum. DLP ID: *toxic erythema 4519*. Courtesy of Dr D Wallach, Paris, France



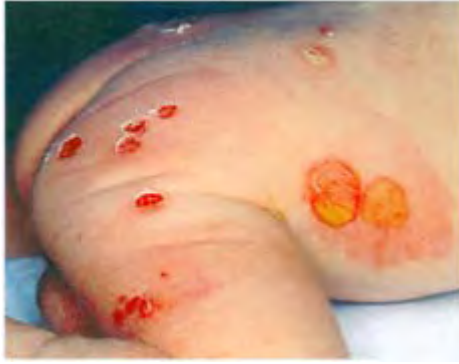**Figure 1.8** Focal dermal hypoplasia (Goltz-Gorlin syndrome) with trophic ulcer. DLP ID: *focal dermal hypoplasia 3430*. Courtesy of Dr A Metzker, Tel Aviv, Israel



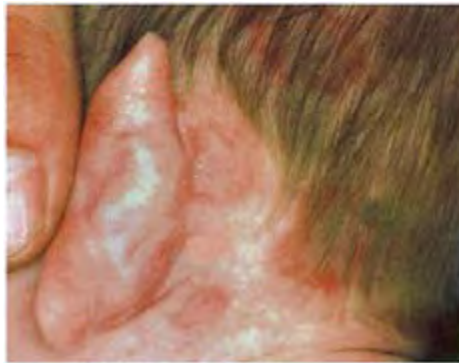**Figure 1.9** Focal dermal hypoplasia (Goltz-Gorlin syndrome) with trophic ulcer. DLP ID: *focal dermal hypoplasia 3430*. Courtesy of Dr A Metzker, Tel Aviv, Israel



**Figure 1.10** Herpes simplex infection. DLP ID: *herpes simplex virus infection 495*. Courtesy of Dr D Wallach, Paris, France

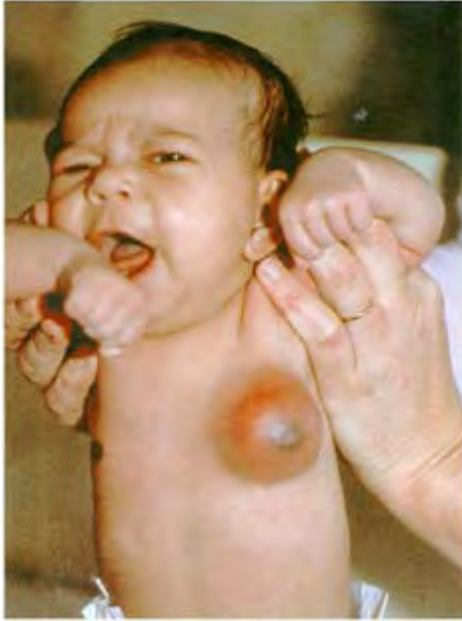

**Figure 1.11** Impetigo, bullous. DLP ID: *bullous impetigo 20*. Courtesy of Dr D Wallach, Paris, France

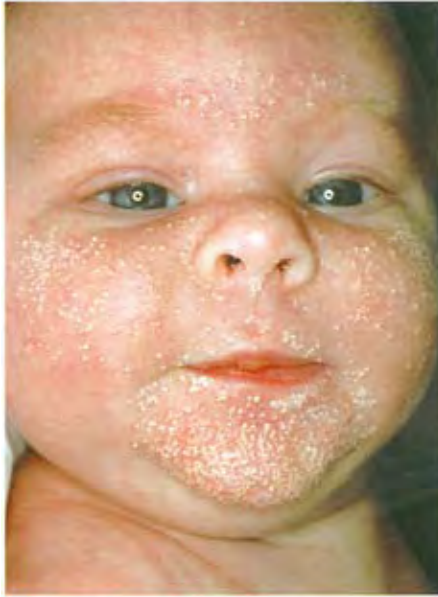

**Figure 1.12** Lupus erythematosus, neonatal. DLP ID: *neonatal lupus erythematosus 1806*. Courtesy of Dr D Wallach, Paris, France

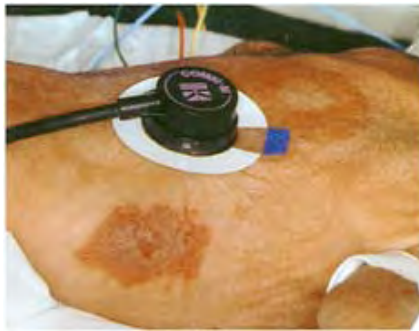



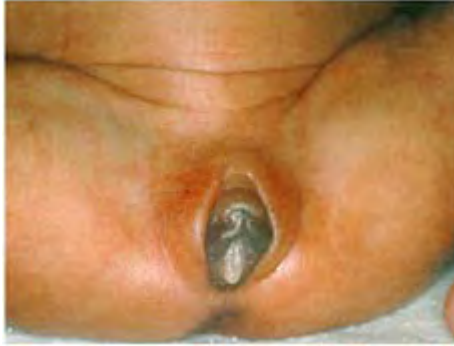**Figure 1.13** Mastitis, acute with abscess formation. DLP ID: *mastitis* 6678. Courtesy of Dr D Wallach, Paris, France



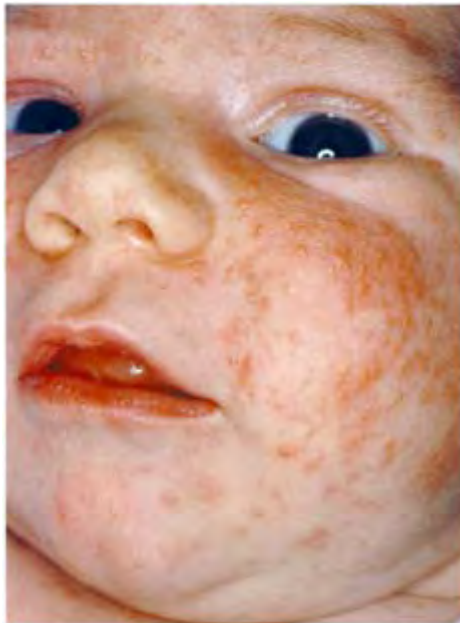**Figure 1.14** Milia, neonatal. DLP ID: *milia 843*. Courtesy of Dr D Wallach, Paris, France



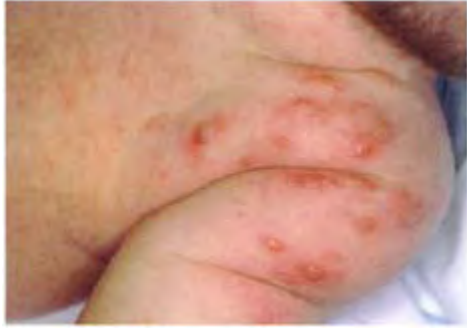**Figure 1.15** Necrosis due to prolonged contact with isopropyl alcohol-containing cleanser. DLP ID: *necrosis/ulceration of skin due to topical drug or skin preparation 5339*. Courtesy of Dr D Wallach, Paris, France



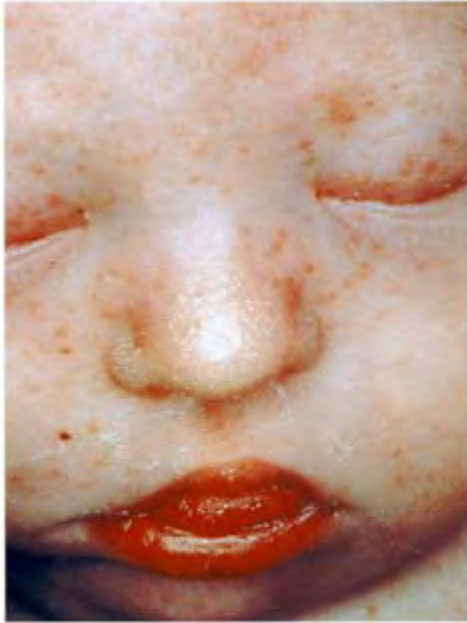**Figure 1.16** Normal vulva of a premature girl (31-week gestation). DLP ID: *normal vulva 5264*. Courtesy of Dr D Wallach, Paris, France



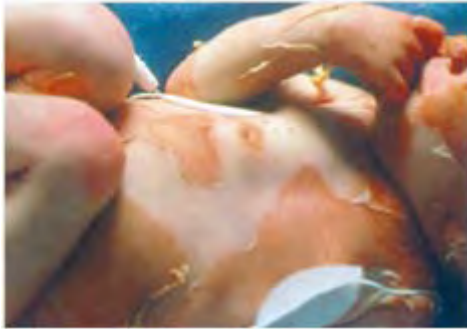**Figure 1.17** Pustulosis of the face due to *Malassezia furfur* (infantile benign cephalic pustulosis). DLP ID: *neonatal cephalic pustulosis 344*. Courtesy of Dr D Wallach, Paris, France



**Figure 1.18** Scabies. DLP ID: *scabies infestation 463*



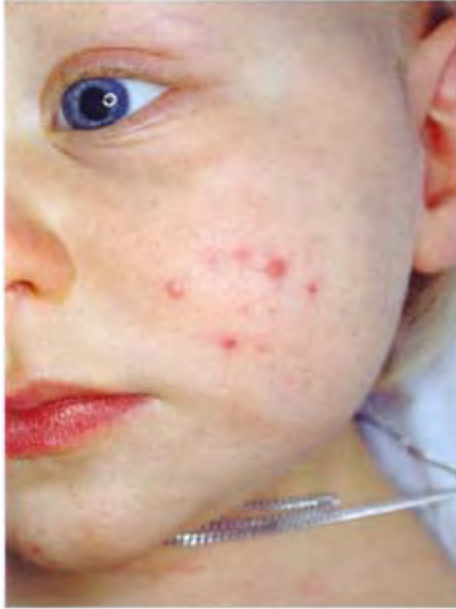**Figure 1.19** Sebaceous gland hyperplasia. DLP ID: *sebaceous hyperplasia 907*. Courtesy of Dr D Wallach, Paris, France



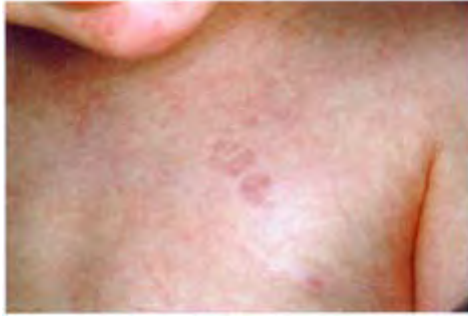**Figure 1.20** Staphylococcal scalded skin syndrome. DLP ID: *Staphylococcal scalded skin syndrome 139*. Courtesy of Dr D Wallach, Paris, France

## 2

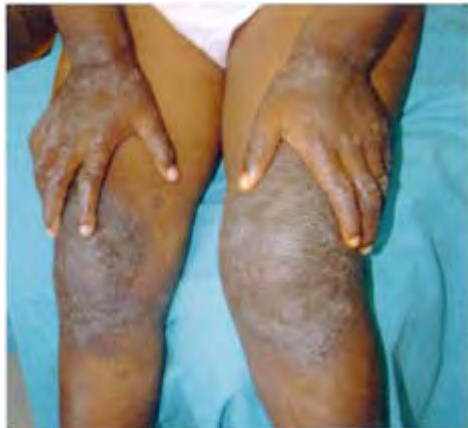### Diseases of young girls



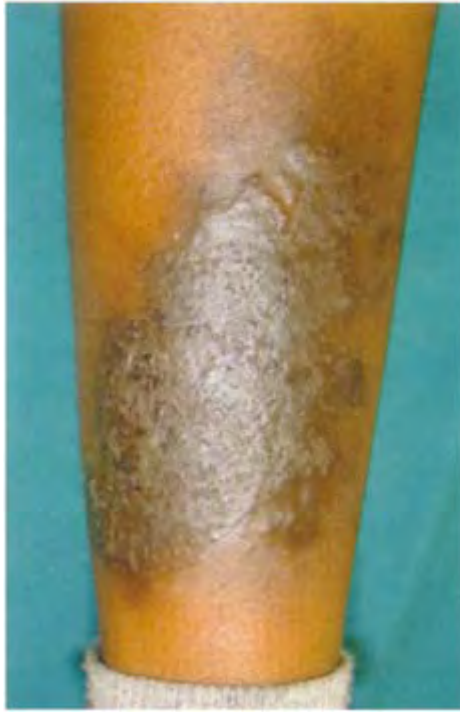**Figure 2.1** Acne, juvenile.  
Dermatology Lexicon Project (DLP)  
preferred term and number: *infantile  
acne 2289*. Courtesy of Dr D Wallach,  
Paris, France



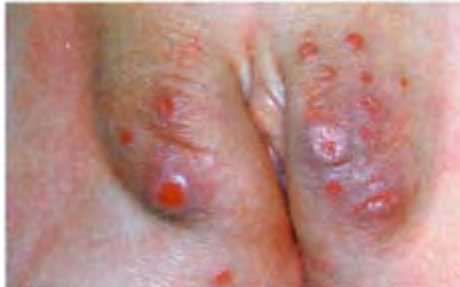**Figure 2.2** Anetoderma attributed to prematurity. DLP ID: *anetoderma of prematurity 1463*



**Figure 2.3** Atopic dermatitis. DLP ID: *atopic dermatitis 2100*. Courtesy of Dr NC Dlova, Durban, South Africa

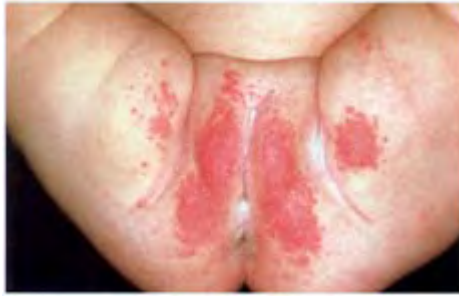

**Figure 2.4** Atopic dermatitis. DLP ID: *atopic dermatitis 2100*. Courtesy of Dr NC Dlova, Durban, South Africa

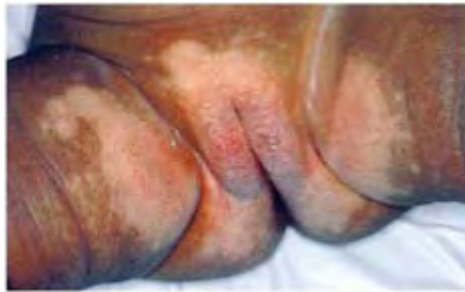

**Figure 2.5** Diaper dermatitis. DLP ID: *diaper irritant dermatitis 2125*. Courtesy of Dr D Wallach, Paris, France

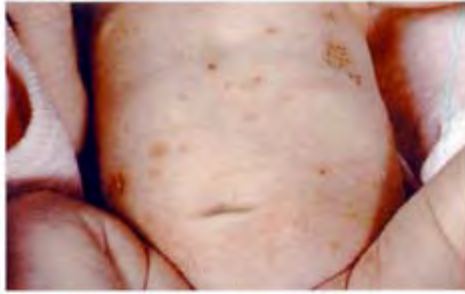



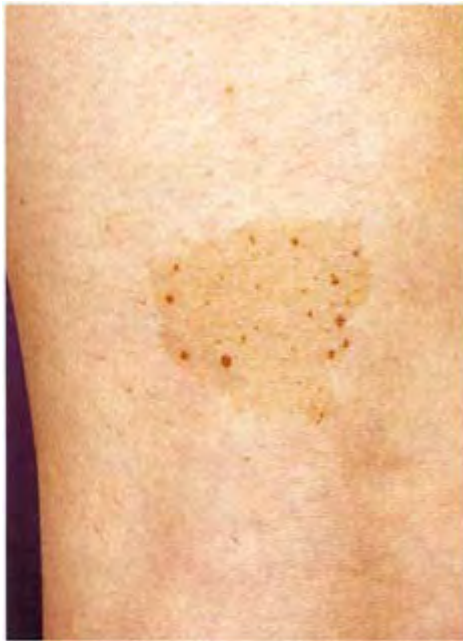**Figure 2.6** Diaper dermatitis, severe (Jacquet's dermatitis). DLP ID: *Jacquet erosive diaper dermatitis 2116*. Courtesy of Dr D Wallach, Paris, France



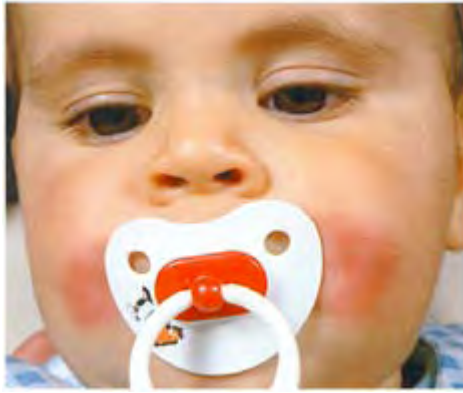**Figure 2.7** Diaper dermatitis, severe, resulting in post-inflammatory hypopigmentation. DLP ID: *diaper irritant dermatitis 2125*. Courtesy of Dr D Wallach, Paris, France



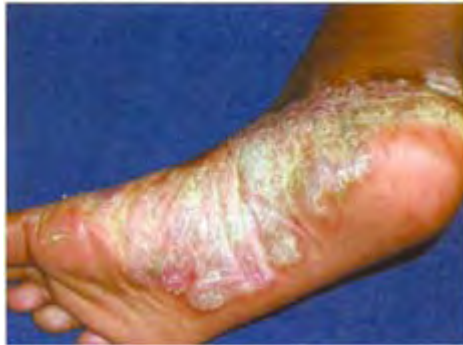**Figure 2.8** Histiocytosis. DLP ID:  
*histiocytosis 1733*



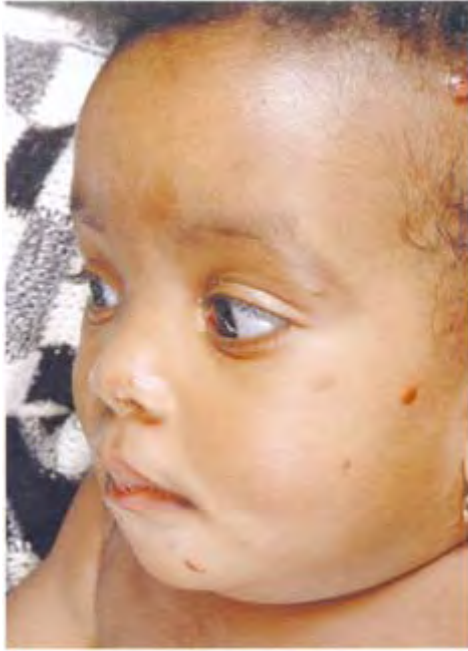**Figure 2.9** Nevus spilus. DLP ID:  
*nevus spilus 990*



**Figure 2.10** Panniculitis due to cold injury. DLP ID: *cold panniculitis 2361*



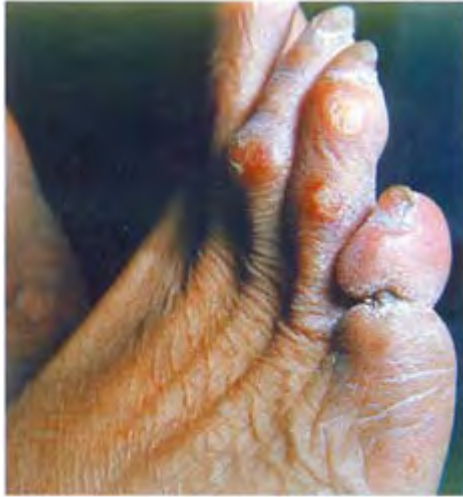**Figure 2.11** Psoriasis. DLP ID: *psoriasis 2042*



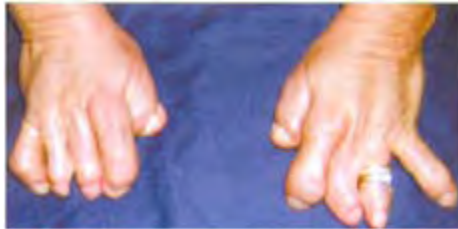**Figure 2.12** Xanthogranuloma, juvenile. DLP ID: *juvenile xanthogranuloma 4381*

### 3

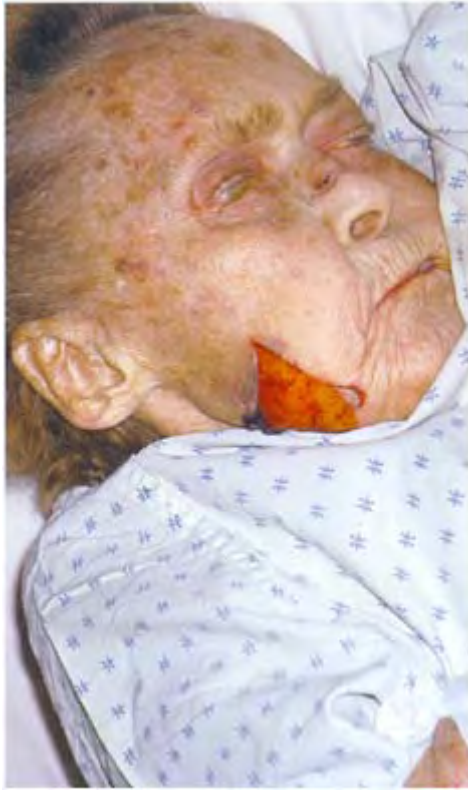## Genodermatoses



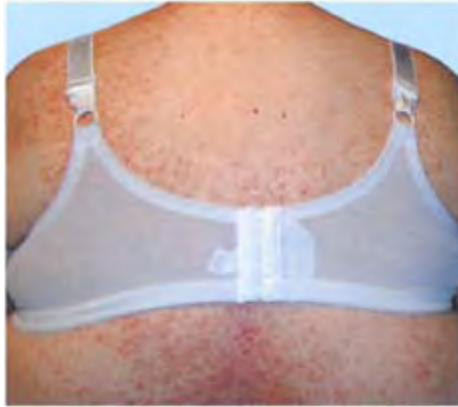**Figure 3.1** Ainhum. Dermatology Lexicon Project (DLP) preferred term and number: *ainhum 3404*



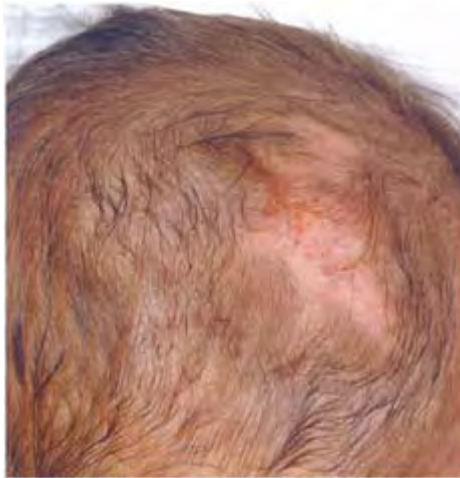**Figure 3.2** Apert syndrome (acrocephalosyndactyly). DLP ID: *Apert syndrome 3406*



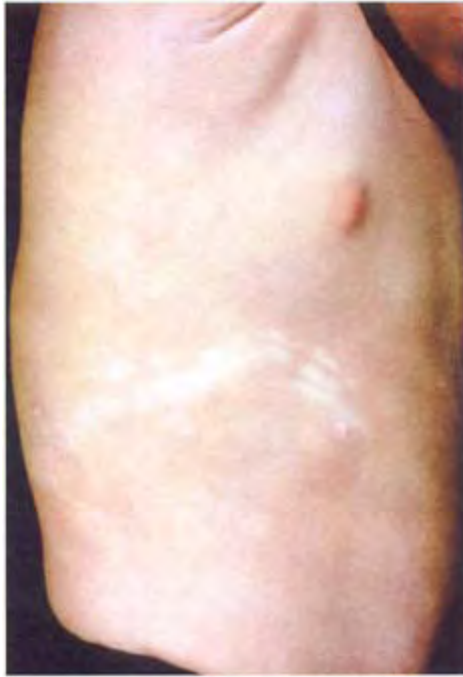**Figure 3.3** Cutis laxa. DLP ID: *cutis laxa 2245*. Courtesy of Dr B Mevorach, Tel Aviv, Israel



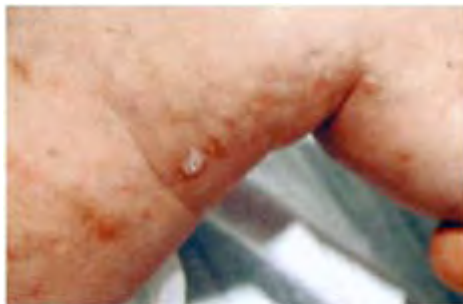**Figure 3.4** Darier's disease (keratosis follicularis). DLP ID: *Darter's disease 3078*



**Figure 3.5** Goltz syndrome (focal dermal hypoplasia). DLP ID: *focal dermal hypoplasia 3430*

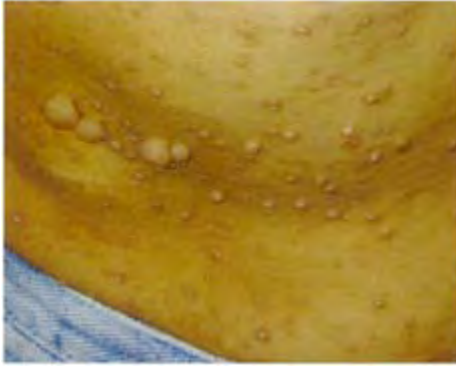

**Figure 3.6** Incontinentia pigmenti achromians (hypomelanosis of Ito).  
DLP ID: *hypomelanosis of Ito 1035*

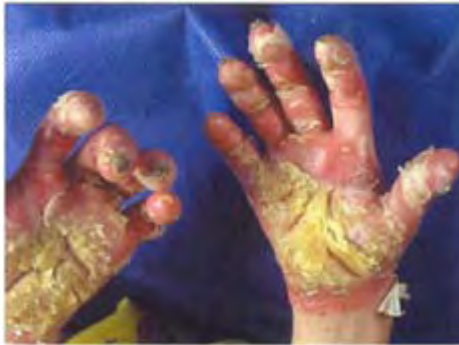

**Figure 3.7** Incontinentia pigmenti (Bloch-Sulzberger syndrome). DLP ID: *incontinentia pigmenti 3239*

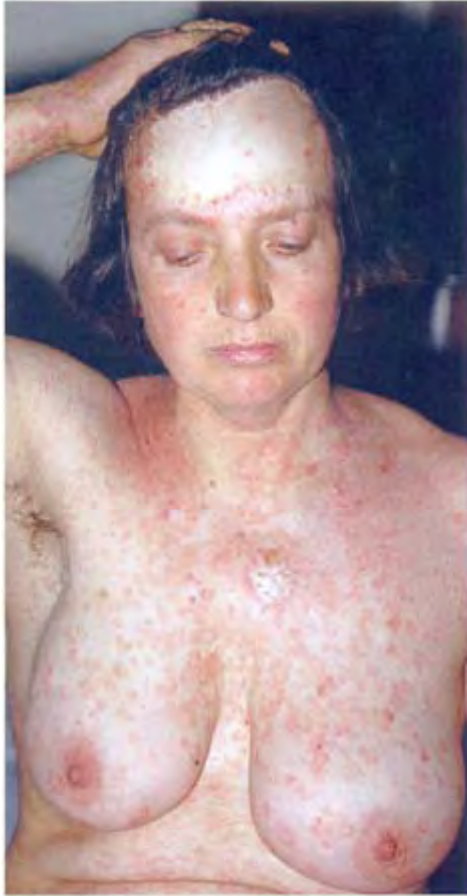



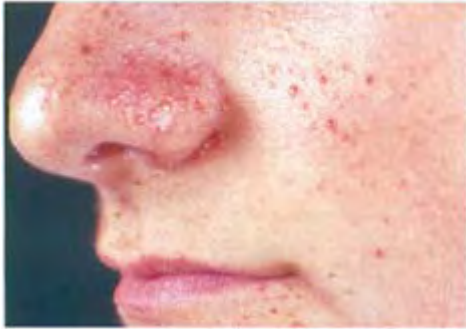**Figure 3.8** Neurofibromatosis (von Recklinghausen syndrome) showing neurofibromas. DLP ID: *neurofibromatosis 2936*



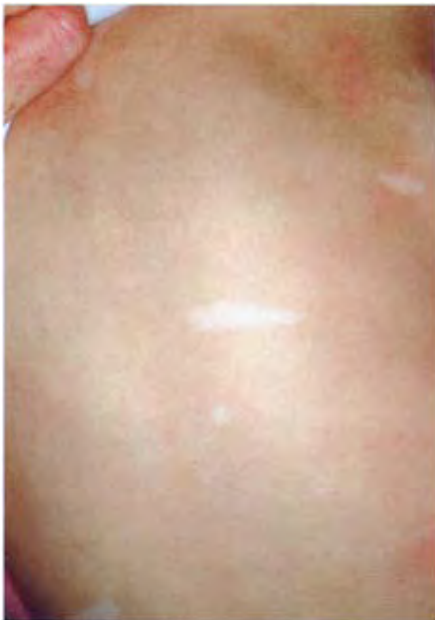**Figure 3.9** Olmstead syndrome (mutilating palmoplantar keratoderma). DLP ID: *Olmstead syndrome 3056*. Courtesy of Dr B Mevorach, Tel Aviv, Israel



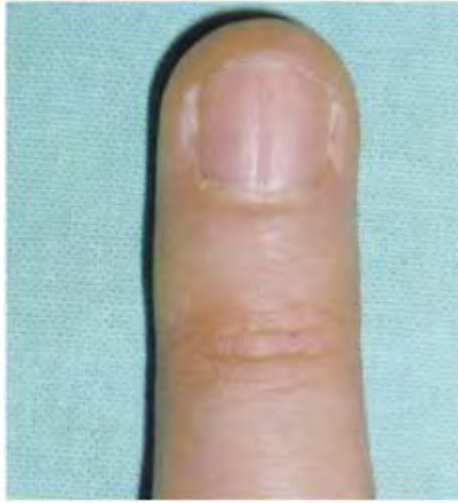**Figure 3.10** Pseudoxanthoma elasticum. DLP ID: *pseudoxanthoma elasticum 3398*



**Figure 3.11** Tuberous sclerosis showing adenoma sebaceum (Bourneville's disease). DLP ID: *tuberous sclerosis 2951*. Courtesy of Dr B Mevorach, Tel Aviv, Israel



**Figure 3.12** Tuberous sclerosis showing ash-leaf hypomelanotic macule (Bourneville's disease). DLP ID: *tuberous sclerosis 2951*. Courtesy of Dr D Wallach, Paris, France

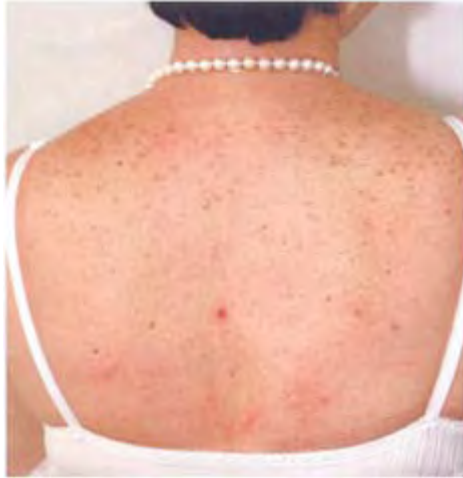

**Figure 3.13** Tuberous sclerosis showing a periungual fibroma (Bourneville's disease). DLP ID: *tuberous sclerosis 2951*. Courtesy of Dr D Wallach, Paris, France

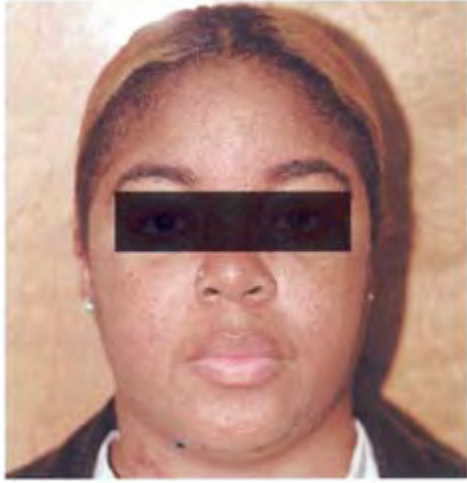Diseases of skin structure—  
non-hereditary

## 4

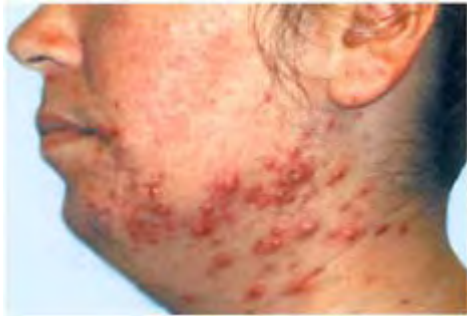### Disorders of the sebaceous, apocrine, and eccrine glands



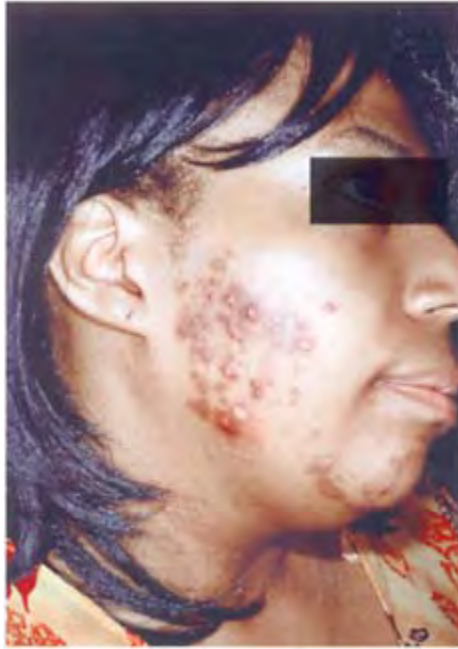**Figure 4.1** Acne aggravated by oral steroids. Dermatology Lexicon Project (DLP) preferred term and number: *steroid induced acne 2295*



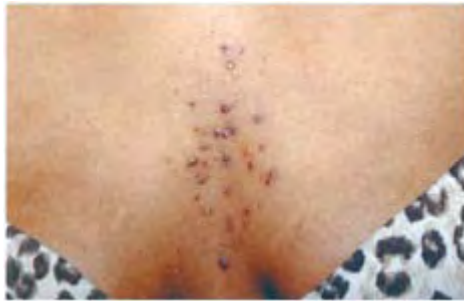
**Figure 4.2** Acne aggravated by Vaseline<sup>®</sup>. DLP ID: *pomade acne 2300*



**Figure 4.3** Acne conglobata. DLP ID: *acne conglobata 2318*

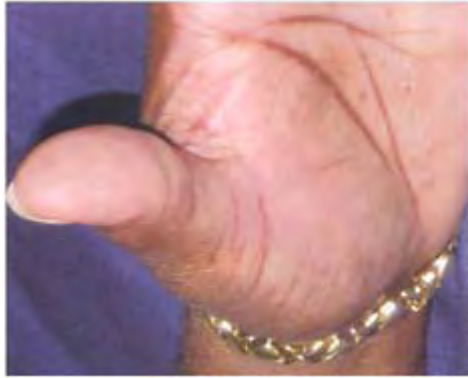

**Figure 4.4** Acne excoriée de jeune fille. DLP ID: *acne excoriee 653*

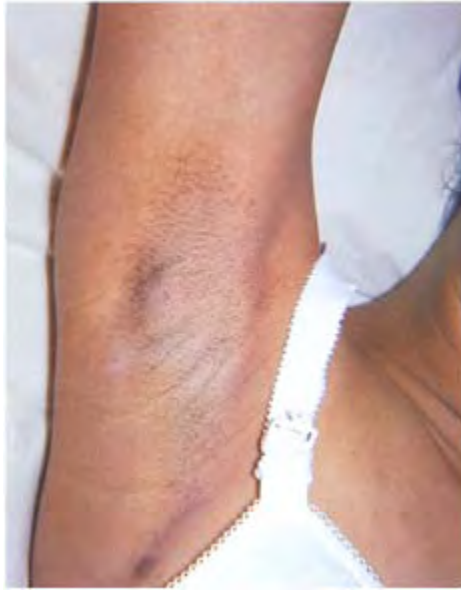

**Figure 4.5** Acne keloidalis. DLP ID: *acne keloidalis 2321*

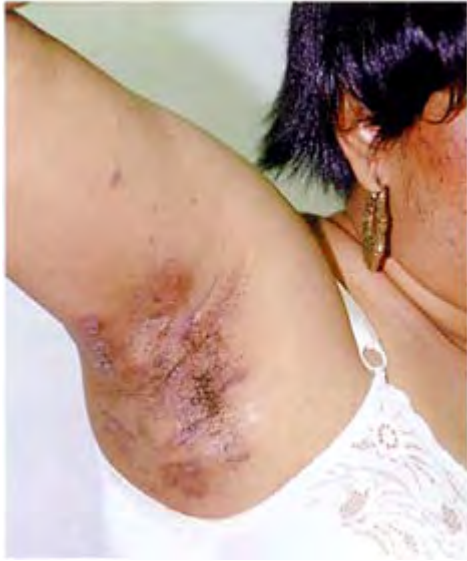



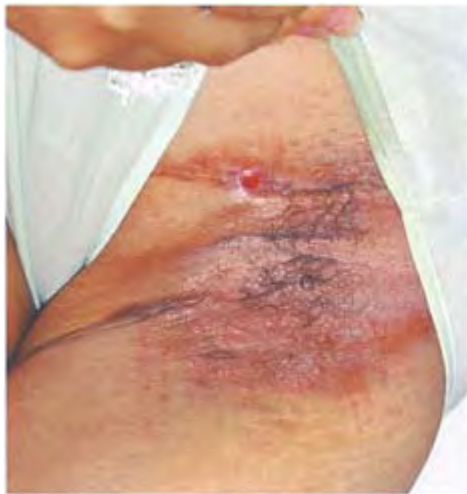**Figure 4.6** Dyshidrosis. DLP ID:  
*dyshidrotic dermatitis 2107*



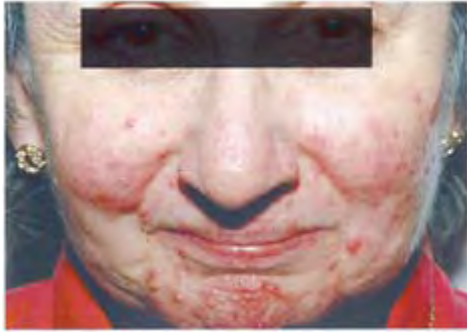
**Figure 4.7** Fox-Fordyce disease. DLP  
ID: *Fox-Fordyce disease 2348*



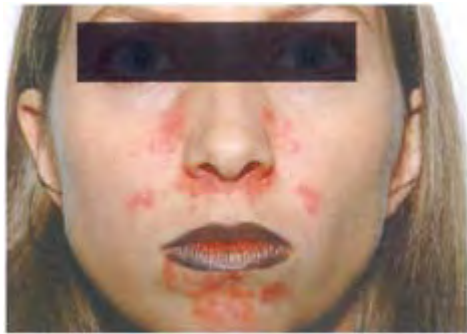**Figure 4.8** Hidradenitis suppurativa in the axilla. DLP ID: *hidradenitis suppurativa 2317*



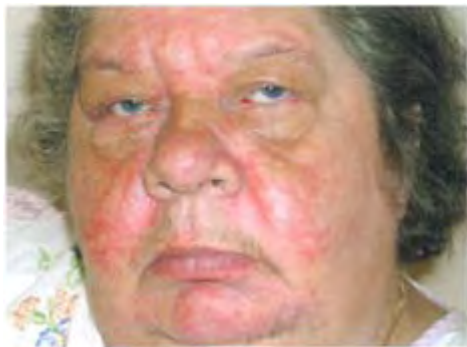**Figure 4.9** Hidradenitis suppurativa in the inguinal area. DLP ID: *hidradenitis suppurativa 2317*



**Figure 4.10** Perioral dermatitis. DLP ID: *perioral dermatitis 2313*



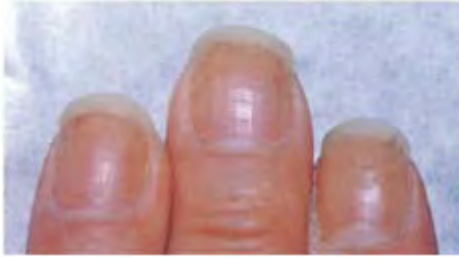**Figure 4.11** Rosacea. DLP ID: *rosacea 2283*



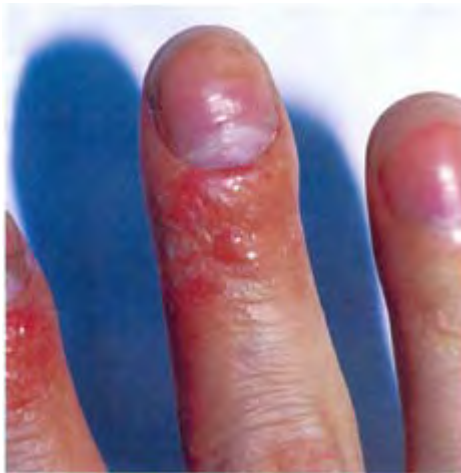**Figure 4.12** Rosacea with rhinophyma in a woman with hyperandrogenism. DLP ID: *rosacea 2283*

## 5

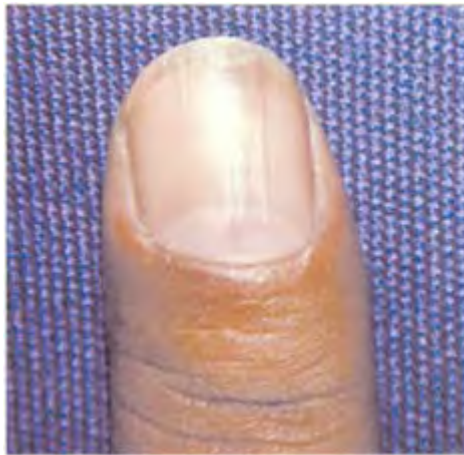### Disorders of the nails



**Figure 5.1** Alopecia areata with Scotch plaiding. Dermatology Lexicon Project (DLP) preferred term and number: *alopecia areata 1841*



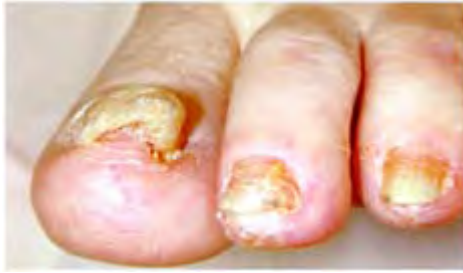**Figure 5.2** Clubbing of distal phalanges. DLP ID: *idiopathic clubbing of fingers 4494*



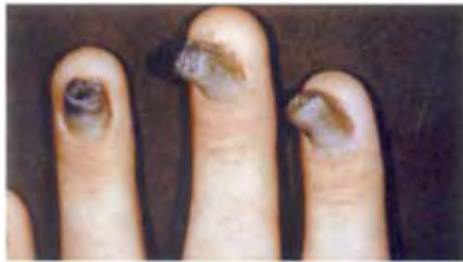**Figure 5.3** Glomangioma. DLP ID: *glomangioma 1468*. Courtesy of Dr A d'Acari, Rio de Janeiro, Brazil



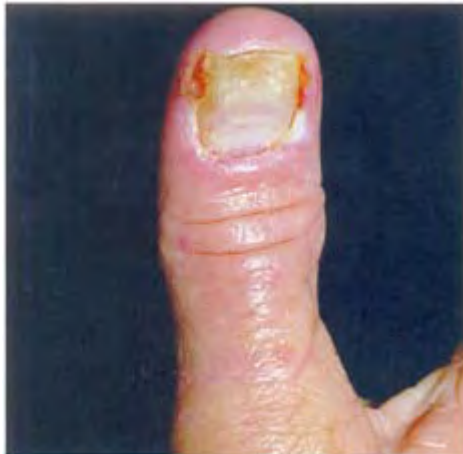**Figure 5.4** Melanonychia, benign, longitudinal due to nevus, pigmented. DLP ID: *melanonychia striata 1082*



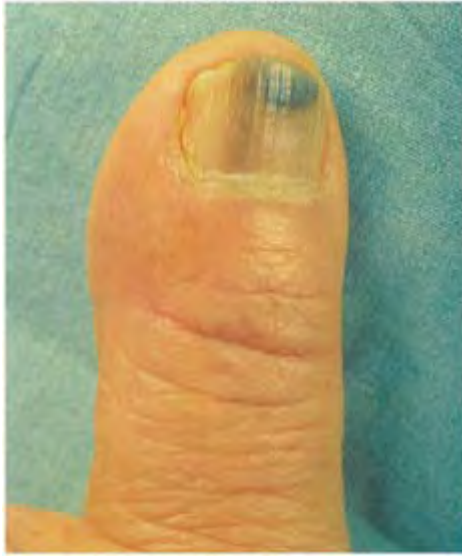**Figure 5.5** Onychomycosis. DLP ID: *onychomycosis 4935*



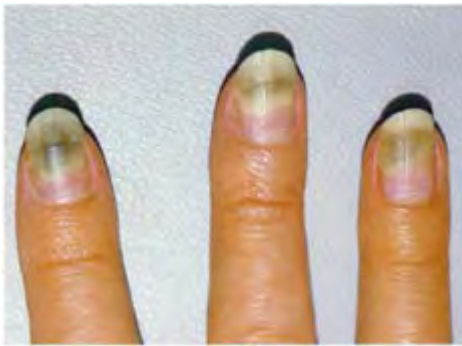
**Figure 5.6** Pachyonychia congenita. DLP ID: *pachyonychia congenita 3270*



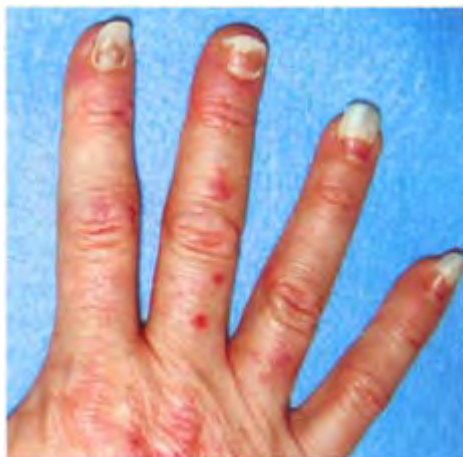**Figure 5.7** Paronychia due to *Candida albicans*. DLP ID: *paronychia candidiasis 362*



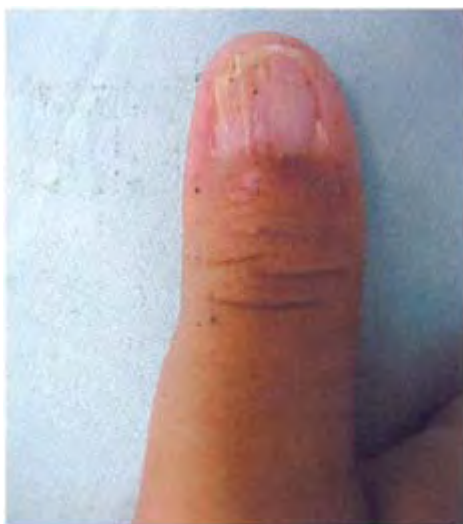**Figure 5.8** Pigmentation due to hydroxyurea therapy for polycythemia vera. DLP ID: *nail pigment, drug induced 4222*



**Figure 5.9** Pseudomonas nail infection. DLP ID: *pseudomonas nail infection 4816*

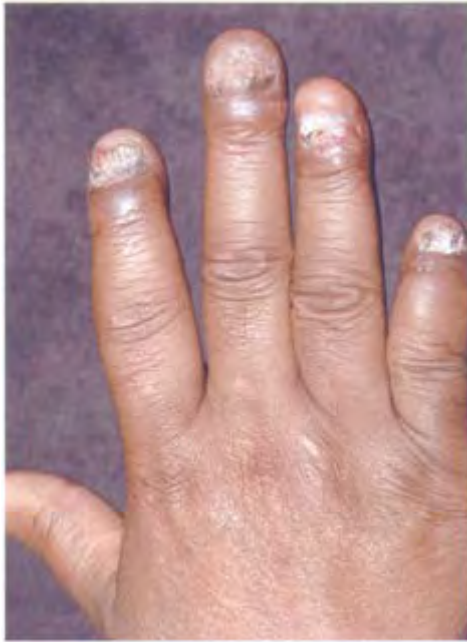

**Figure 5.10** Psoriatic nails. DLP ID:  
*psoriasis of the nails 4751*

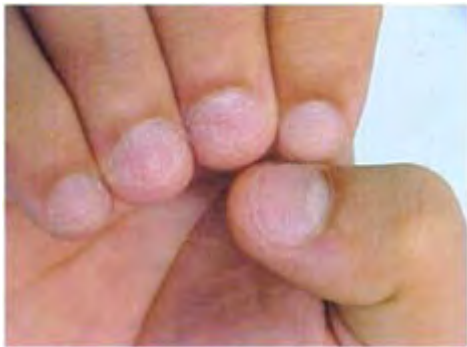

**Figure 5.1 I** Pterygium. DLP ID:  
*pterygium 4799*. Courtesy of Dr T  
Cestari, Porto Alegre, Brazil





**Figure 5.12** Sarcoidosis. DLP ID:  
*sarcoidosis 2203*



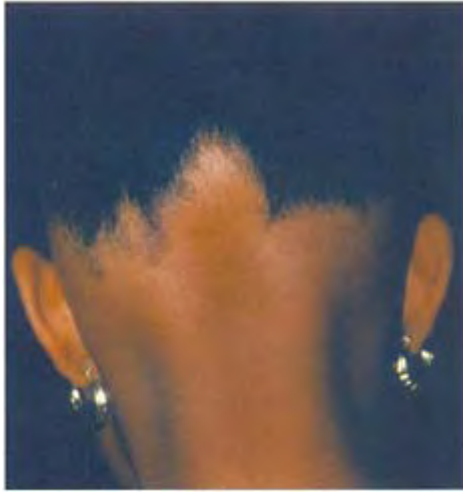**Figure 5.13** Trachyonychia. DLP ID:  
*trachyonychia 3928*

## 6

### Disorders of the hair and the scalp



**Figure 6.1** Alopecia androgenica.  
Dermatology Lexicon Project (DLP)  
preferred term and number: *patterned  
hair loss 3737*



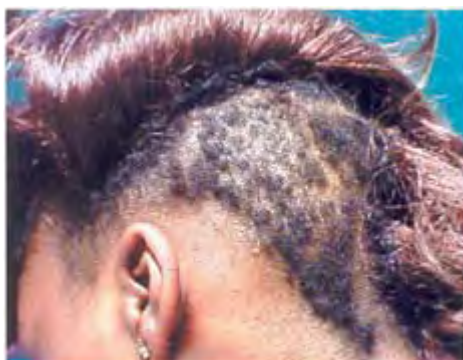**Figure 6.2** Alopecia areata. DLP ID: *alopecia areata 1841*



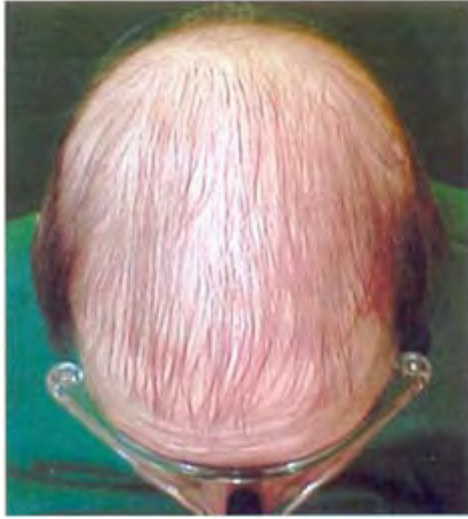**Figure 6.3** Alopecia due to hot combs. DLP ID: *hot comb alopecia 4663*



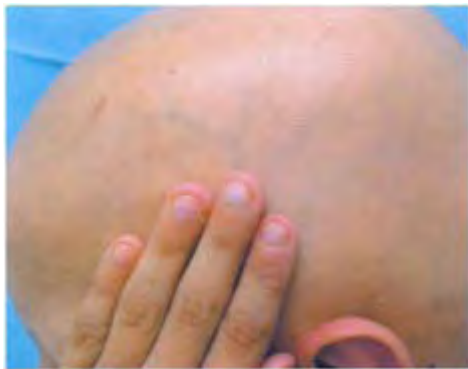**Figure 6.4** Alopecia due to traction from braiding. DLP ID: *traction alopecia 3860*



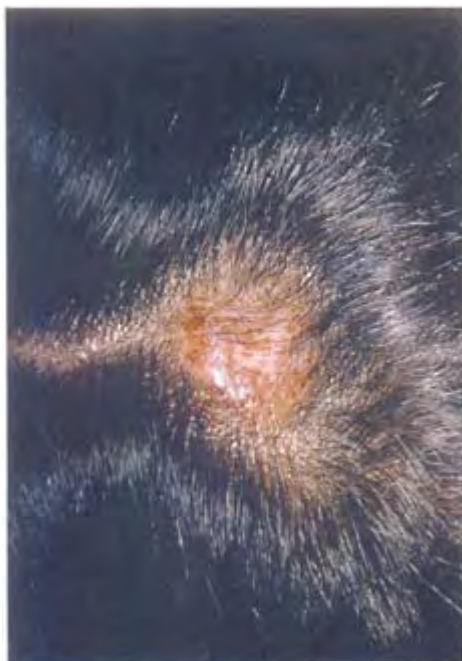
**Figure 6.5** Alopecia due to traction from curlers. DLP ID: *traction alopecia 3860*. Courtesy of Dr D Van Neste, Tournai, Belgium



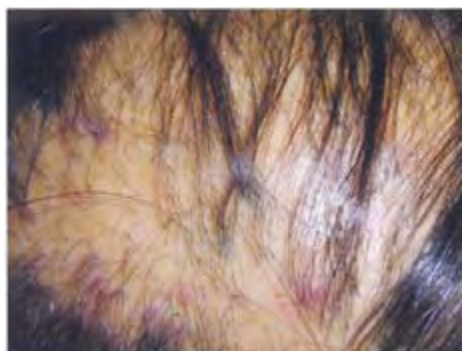**Figure 6.6** Alopecia, permanent following chemotherapy for breast cancer with docetaxel. DLP ID: *alopecia (unclassified) 4950*. Courtesy of Dr D Van Neste, Tournai, Belgium



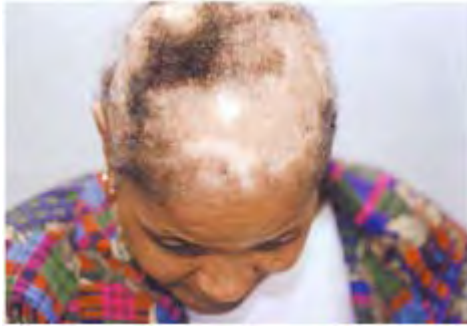**Figure 6.7** Alopecia totalis with Scotch plaiding of nails. DLP ID: *alopecia totalis 3782*



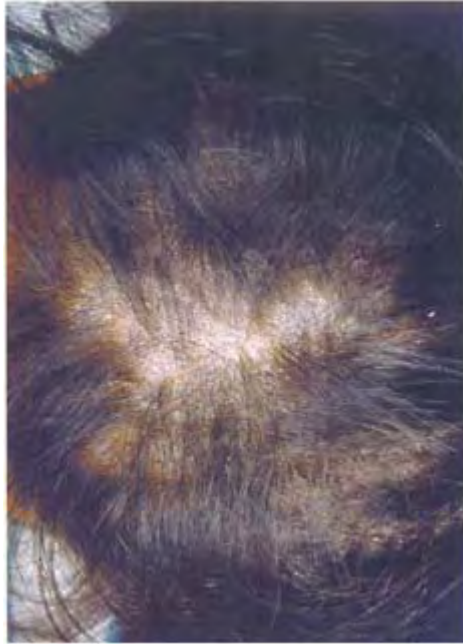
**Figure 6.8** Lichen planopilaris (Graham-Little syndrome). DLP ID: *lichen planopilaris 2152*



**Figure 6.9** Lichen planopilaris (Graham-Little syndrome). DLP ID: *lichen planopilaris (Graham-Little syndrome) 2152*. Courtesy of Drs C Sodre and G Munhoz-da-Fontoura, Rio de Janeiro, Brazil



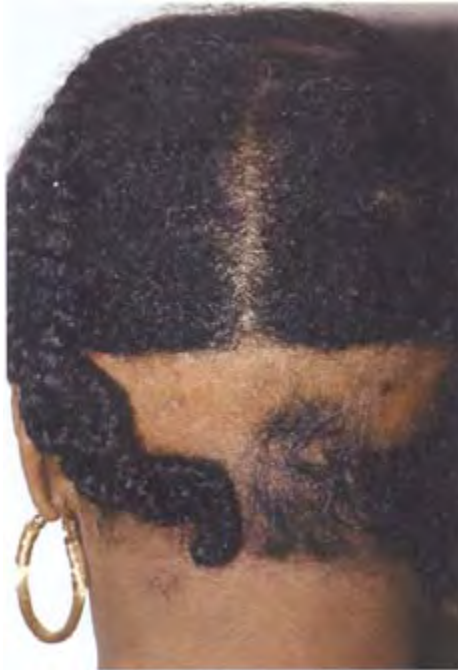**Figure 6.10** Lupus erythematosus, discoid with alopecia. DLP ID: *discoid lupus erythematosus, 1803*



**Figure 6.11** Lupus erythematosus, systemic with alopecia. DLP ID: *systemic lupus erythematosus, 1808*

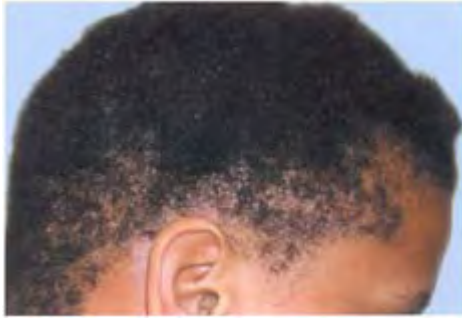

**Figure 6.12** Nevus, woolly hair. DLP ID: *woolly hair nevus 4525*

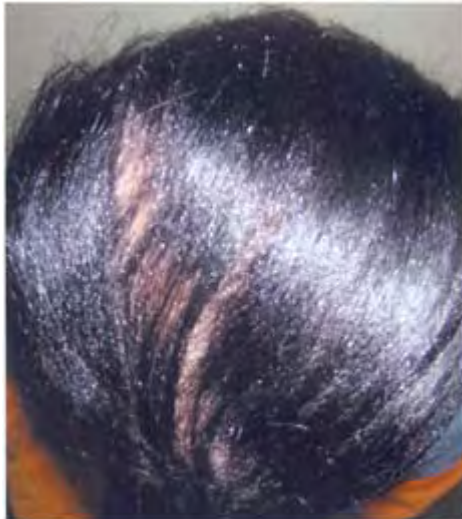

**Figure 6.14** Perifolliculitis capitis abscedens et suffodiens (dissecting cellulitis of the scalp). DLP ID: *dissecting cellulitis of the scalp 2319*

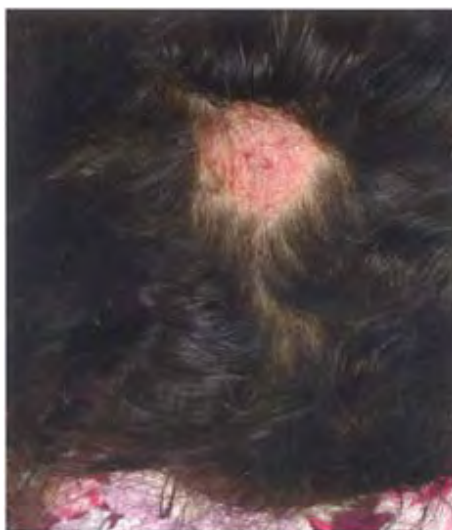



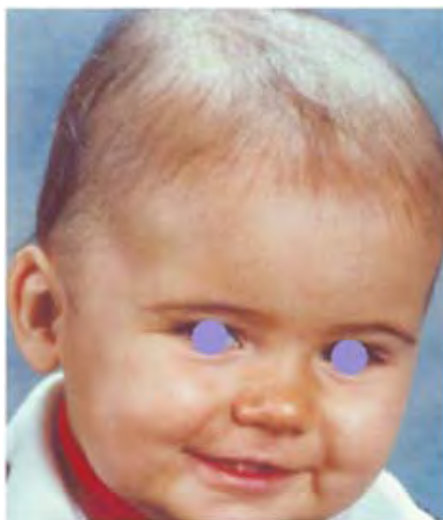**Figure 6.13** Ophiasis. DLP ID:  
*ophiasis 1854*



**Figure 6.15** Pseudopelade of Brocq.  
DLP ID: *pseudopelade of Brocq 5266*



**Figure 6.16** Tinea capitis in an adult due to *Microsporum canis*. DLP ID: *tinea capitis 321*. Courtesy of Dr D Van Neste, Tournai, Belgium



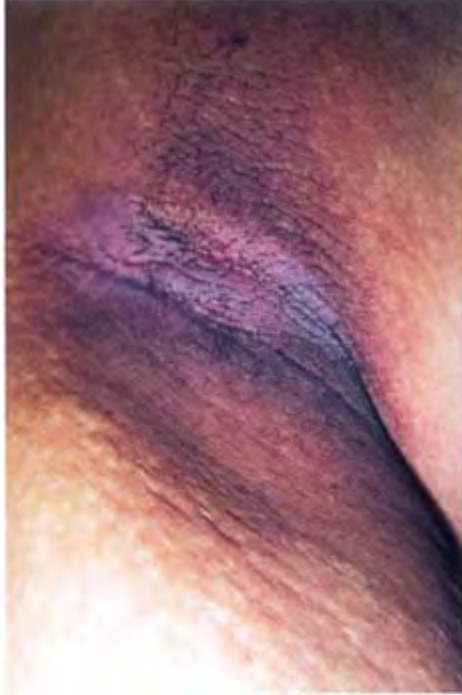**Figure 6.17** Trichothiodystrophy. DLP ID: *trichothiodystrophy 3763*. Courtesy of Dr D Van Neste, Tournai, Belgium



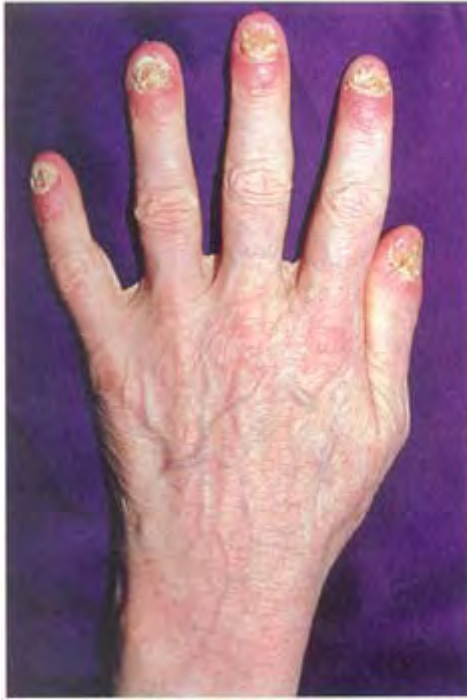# Other diseases



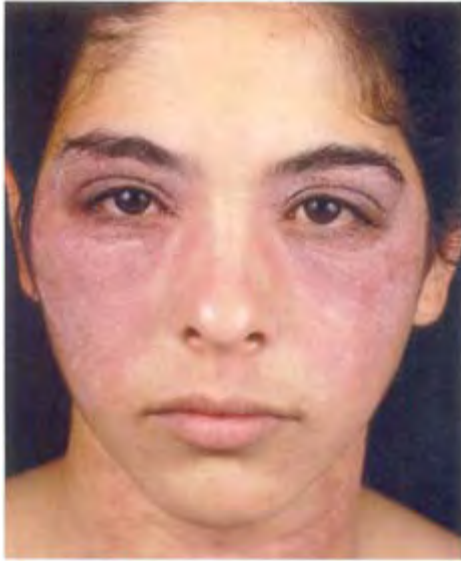## Papulosquamous diseases



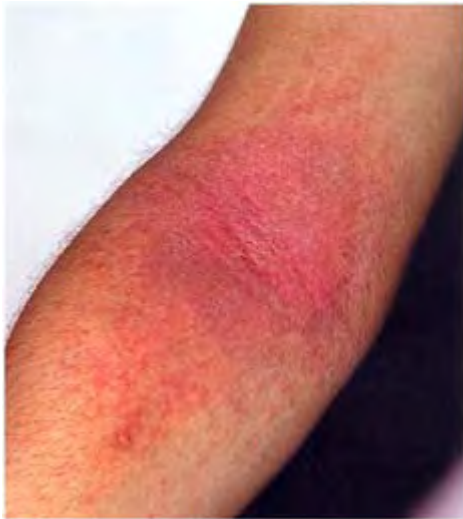**Figure 7.1** Acanthosis nigricans.  
Dermatology Lexicon Project (DLP)  
preferred term and number: *acanthosis nigricans* 2797



**Figure 7.2** Acrodermatitis continua of Hallopeau. DLP ID: *acrodermatitis continua 2050*

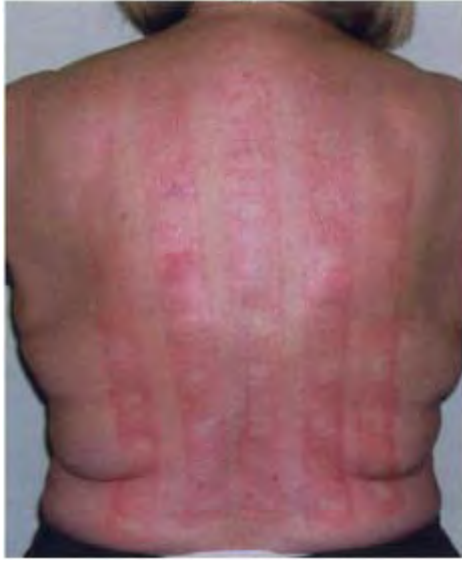

**Figure 7.3** Atopic dermatitis. DLP ID:  
*atopic dermatitis 2100*

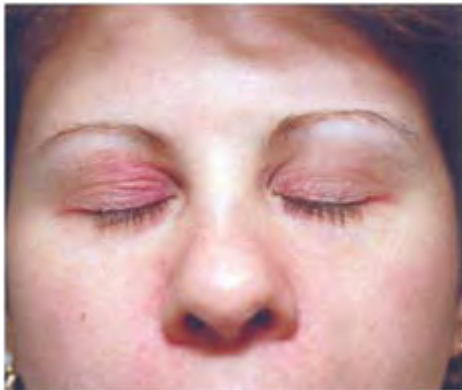

**Figure 7.4** Atopic dermatitis. DLP ID:  
*atopic dermatitis 2100*

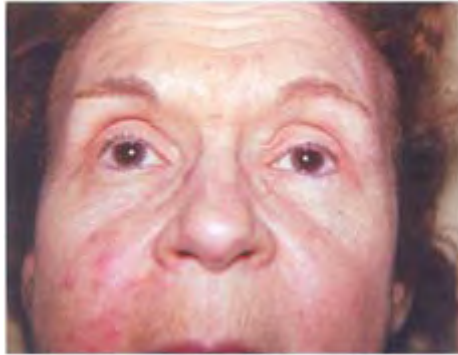



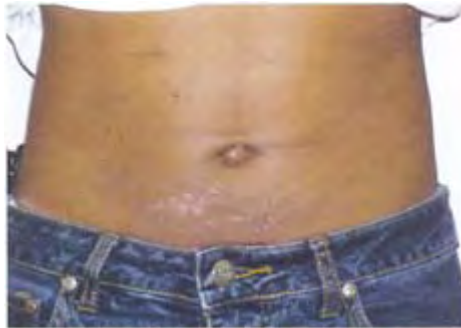**Figure 7.5** Contact dermatitis due to adhesive patches (also shows two positive patch test reactions). DLP ID: *allergic contact dermatitis 2101*



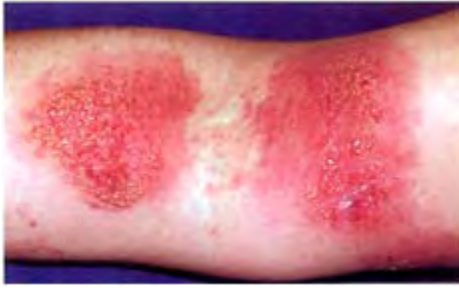**Figure 7.6** Contact dermatitis due to eye cream. DLP ID: *allergic contact dermatitis 2101*



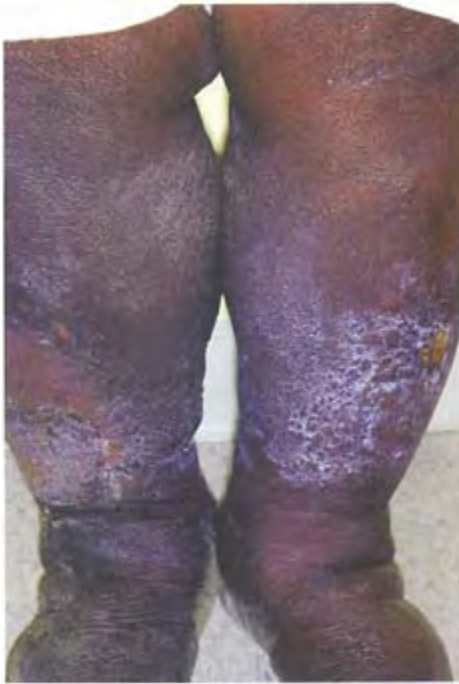**Figure 7.7** Contact dermatitis due to hair dye. DLP ID: *allergic contact dermatitis 2101*



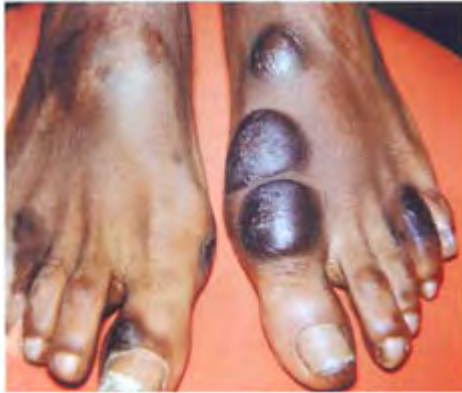**Figure 7.8** Contact dermatitis due to rivet of jeans (nickel-based). DLP ID: *nickel dermatitis 4077*



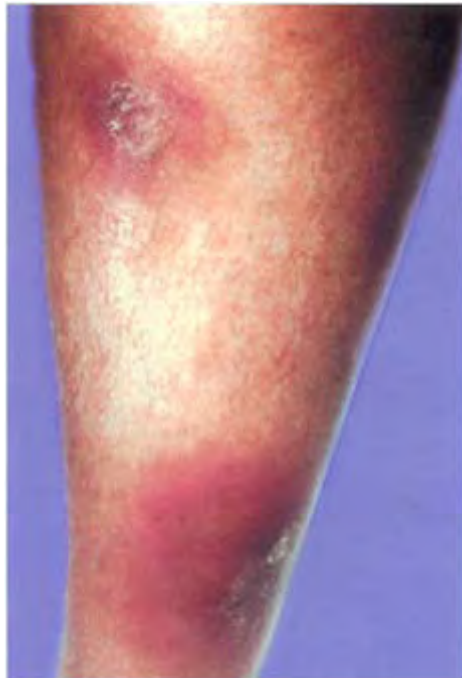**Figure 7.9** Contact dermatitis—rhus dermatitis. DLP ID: *allergic contact dermatitis due to plant 3790*



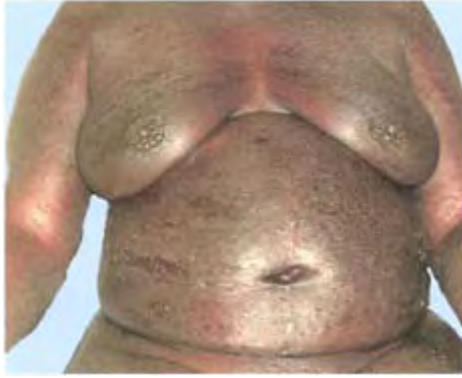**Figure 7.10** Elephantiasis. DLP ID: *elephantiasis verrucosa nostra 2486*



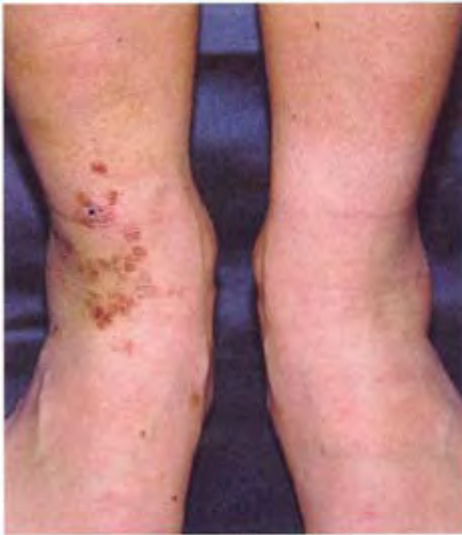**Figure 7.11** Erythema elevatum diutinum. DLP ID: *erythema elevatum diutinum 2013*



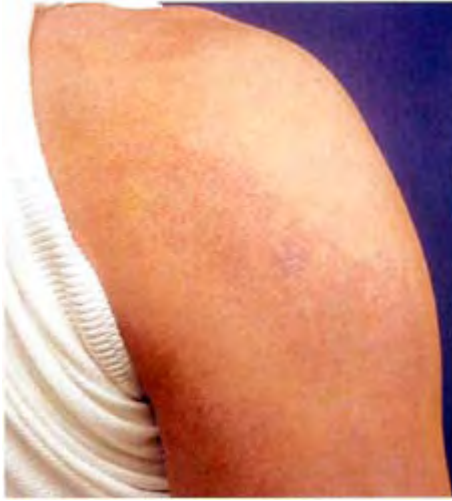**Figure 7.12** Erythema nodosum. DLP ID: *erythema nodosum 2353*



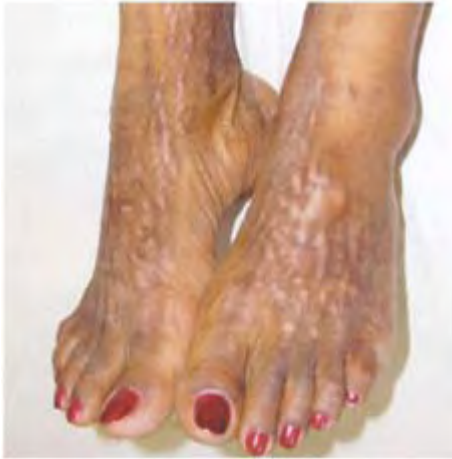**Figure 7.13** Exfoliative erythroderma due to chronic atopic dermatitis. DLP  
ID: *exfoliative dermatitis 2118*



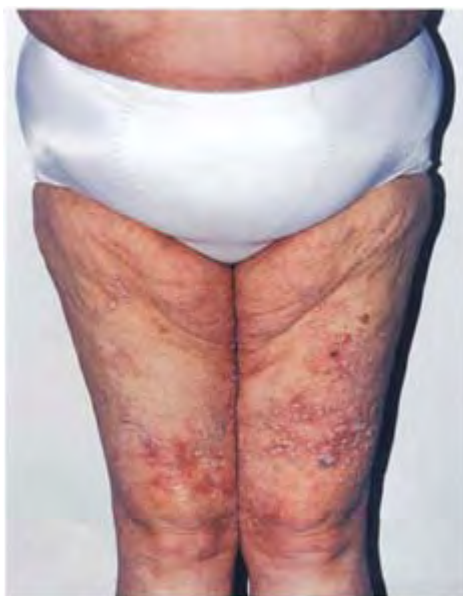**Figure 7.14** Granuloma annulare. DLP  
ID: *granuloma annulare 2200*



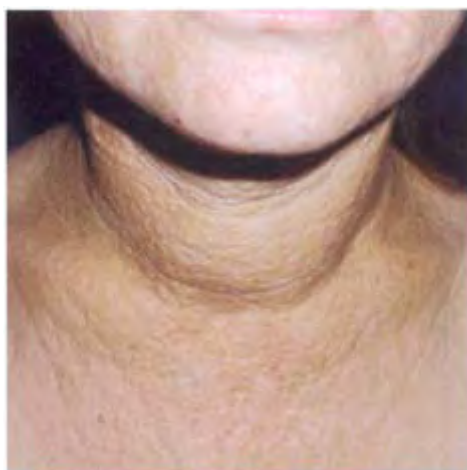**Figure 7.15** Keratosis pilaris. DLP ID: *keratosis pilaris 2324*



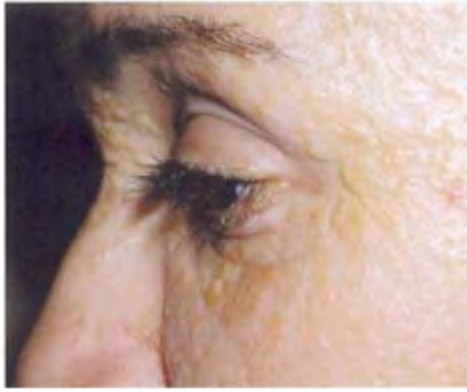**Figure 7.16** Lichen amyloidosis. DLP ID: *lichen amyloidosis 2623*. Courtesy of Dr G Munhoz-da-Fontoura, Rio de Janeiro, Brazil



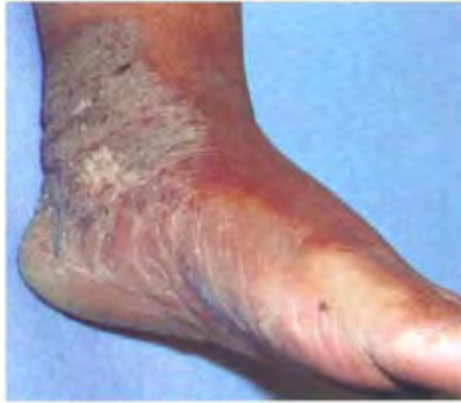**Figure 7.17** Lichen planus. DLP ID: *lichen planus 4843*



**Figure 7.18** Lipoid proteinosis (Urbach-Wiethe syndrome). DLP ID: *lipoid proteinosis 2642*. Courtesy of Drs J Brack and Dr G Munhoz-da-Fontoura, Rio de Janeiro, Brazil

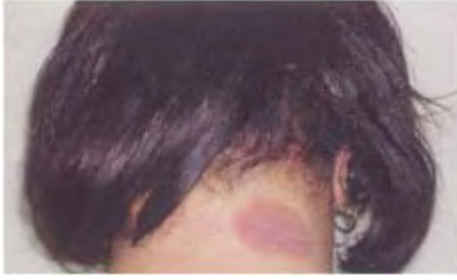

**Figure 7.19** Lipoid proteinosis (Urbach-Wiethe syndrome). DLP ID: *lipoid proteinosis 2642*. Courtesy of Drs J Brack and Dr G Munhoz-da-Fontoura, Rio de Janeiro, Brazil

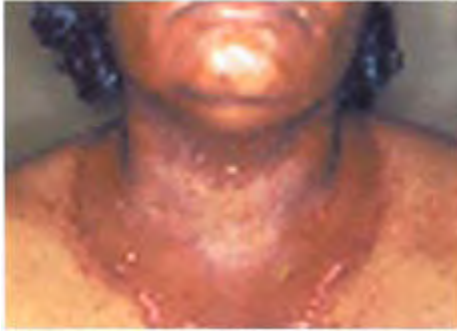

**Figure 7.20** Neurodermatitis. DLP ID: *neurodermatitis 4790*

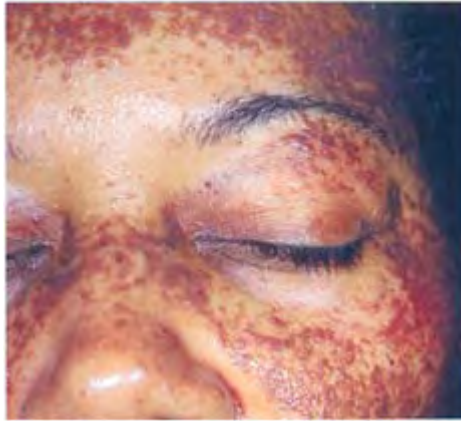



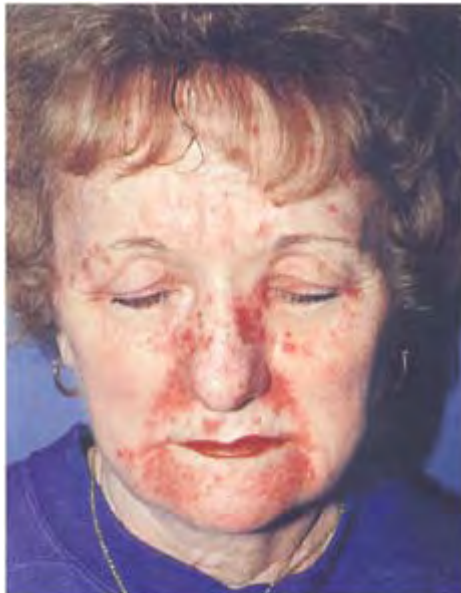**Figure 7.21** Nummular dermatitis.  
DLP ID: *nummular dermatitis 2104*



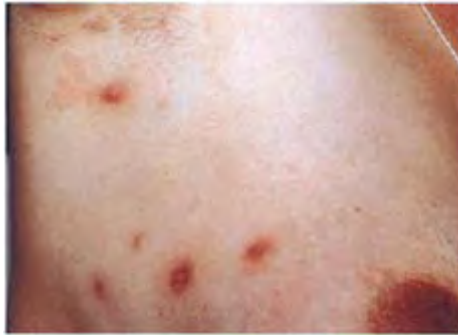**Figure 7.22** Pellagra. DLP ID:  
*pellagra 2740*



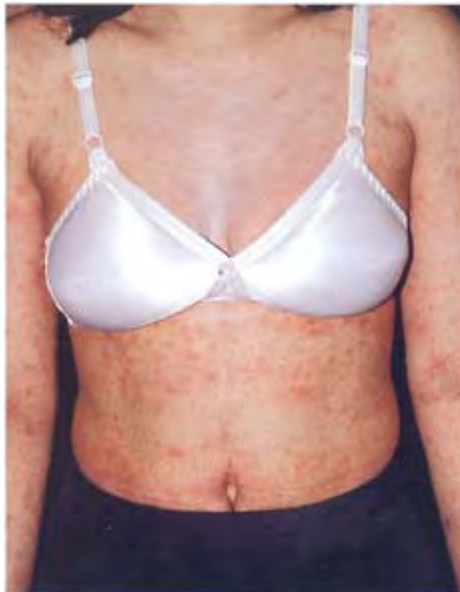**Figure 7.23** Photocontact dermatitis due to celery (phytophotodermatitis). DLP ID: *phytophotodermatitis 2123*



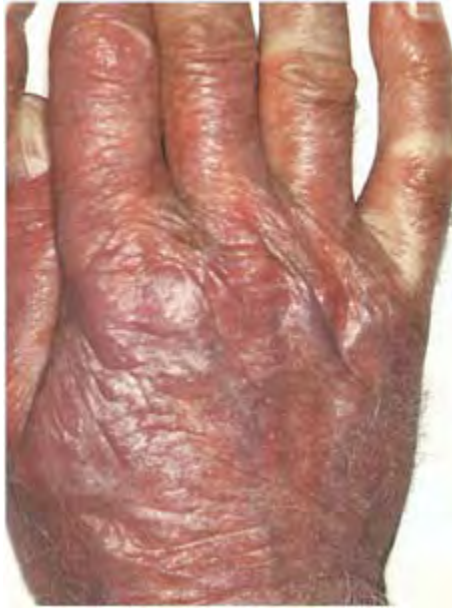**Figure 7.24** Photocontact dermatitis due to 5-fluorouracil. DLP ID: *photoallergic reaction, drug induced 1903*



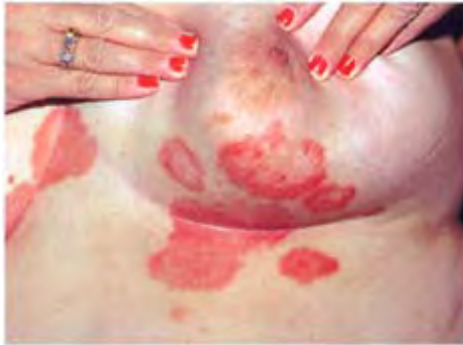**Figure 7.25** Pityriasis lichenoides et varioliformis acuta (PLEVA) (Mucha-Habermann disease). DLP ID: *parapsoriasis lichenoides et varioliformis acuta (PLEVA) 2023*



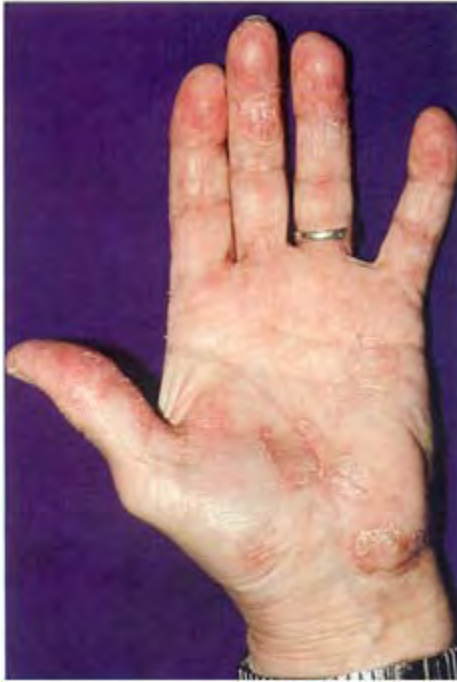**Figure 7.26** Pityriasis rosea. DLP ID: *pityriasis rosea 2058*



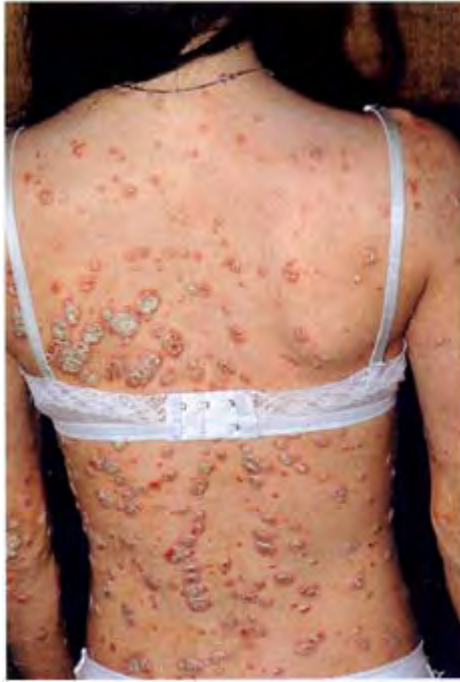**Figure 7.27** Pityriasis rubra pilaris.  
DLP ID: *pityriasis rubra pilaris 2043*



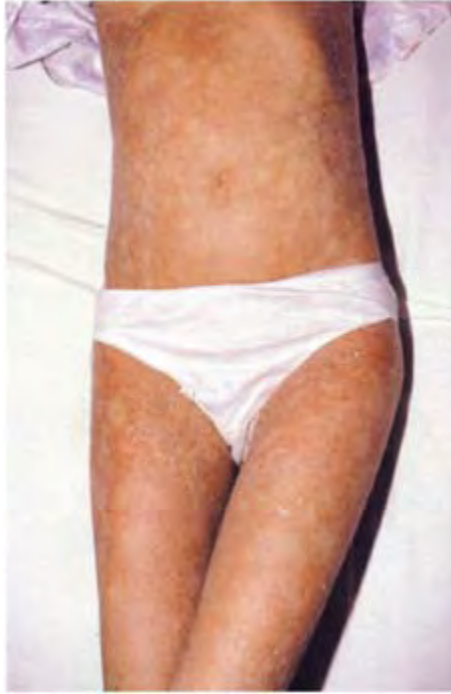**Figure 7.28** Psoriasis. DLP ID:  
*psoriasis 2042*



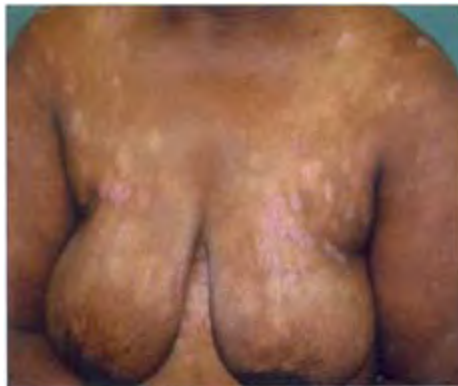**Figure 7.29** Psoriasis. DLP ID:  
*psoriasis 2042*



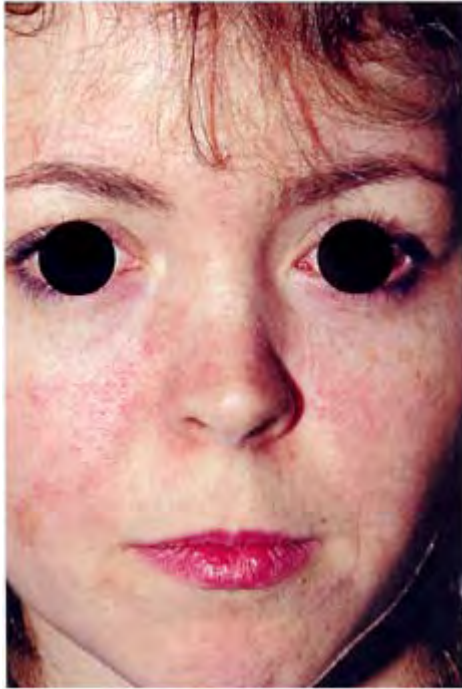**Figure 7.30** Psoriasis. DLP ID:  
*psoriasis 2042*



**Figure 7.31** Psoriasis. DLP ID: *psoriasis 2042*



**Figure 7.32** Psoriasis. DLP ID: *psoriasis 2042*. Courtesy of Dr NC Dlova, Durban, South Africa

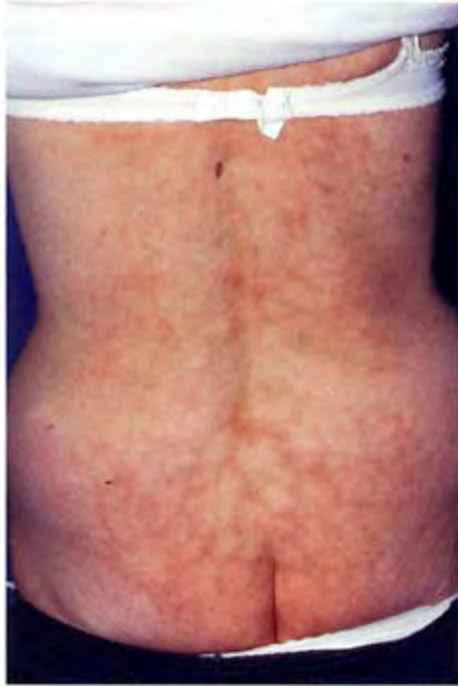

**Figure 7.33** Seborrheic dermatitis.  
DLP ID: *seborrheic dermatitis 2105*

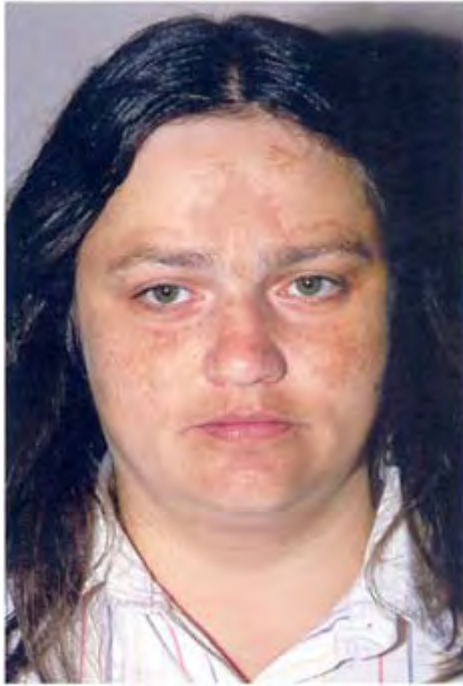

## 8

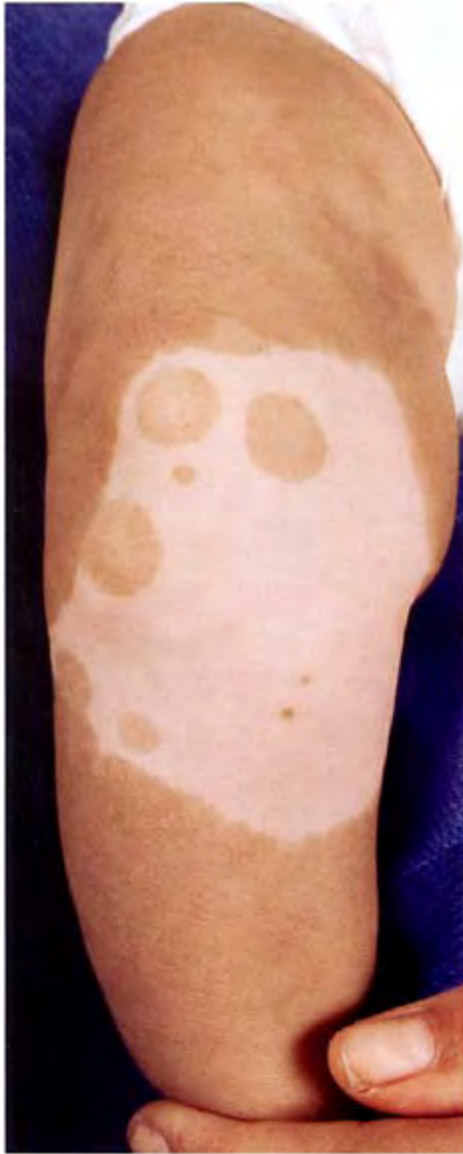### Diseases of pigment changes



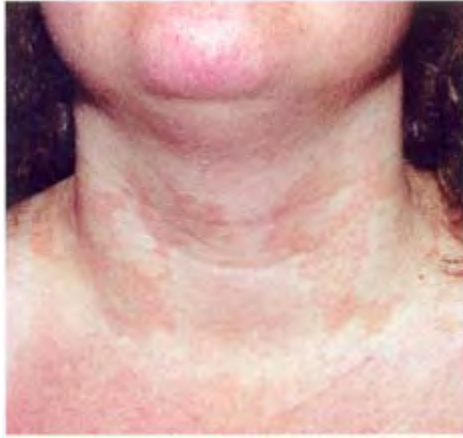**Figure 8.1** Erythema ab igne.  
Dermatology Lexicon Project (DLP)  
preferred term and number: *erythema  
ab igne 4048*



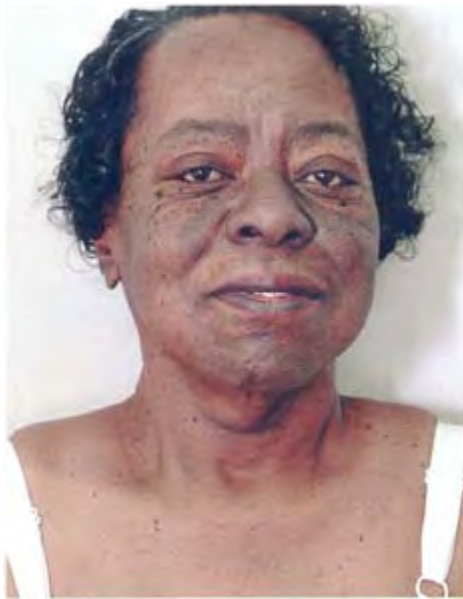**Figure 8.2** Melasma. DLP ID:  
*melasma 4200*



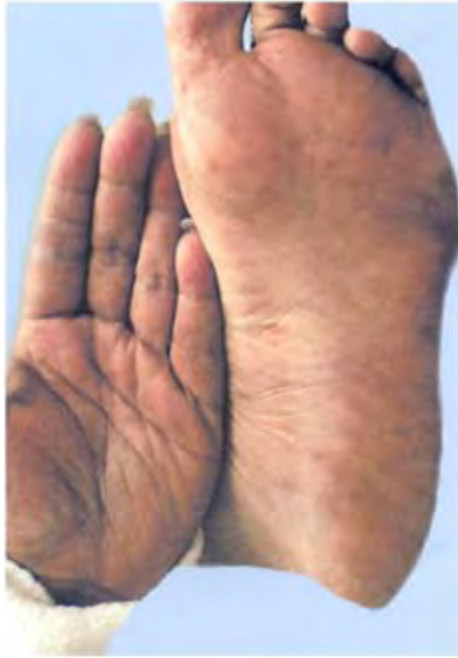**Figure 8.3** Piebaldism. DLP ID:  
*piebaldism 3184*



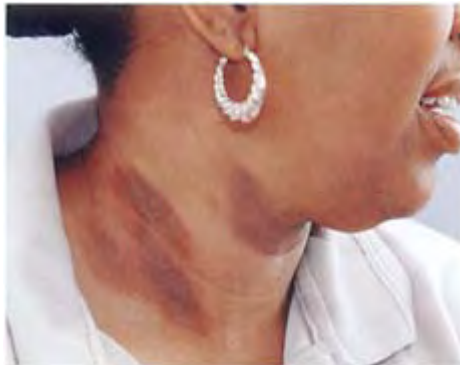**Figure 8.4** Poikiloderma of Civatte.  
DLP ID: *poikiloderma of Civatte 4444*



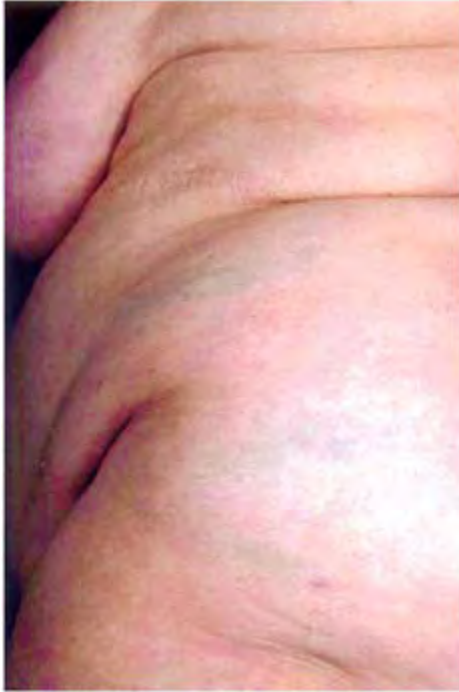**Figure 8.5** Post-inflammatory hyperpigmentation. DLP ID: *post-inflammatory hyperpigmentation 5261*



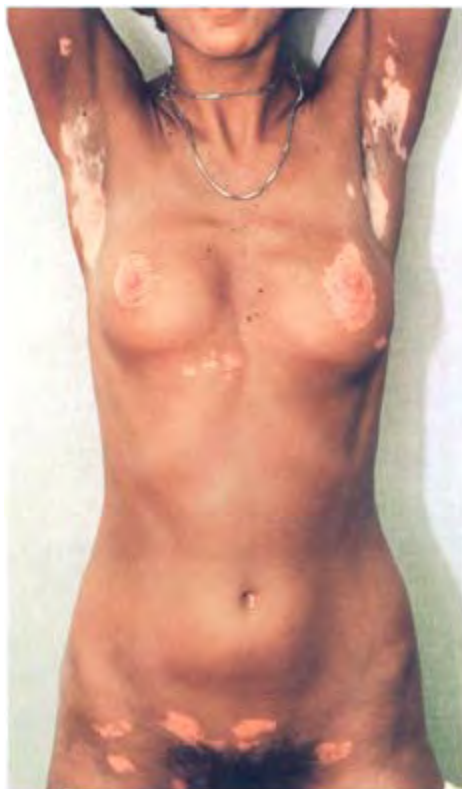**Figure 8.6** Post-inflammatory hyperpigmentation due to doxorubicin therapy for cancer. DLP ID: *hyperpigmentation, drug induced 4942*



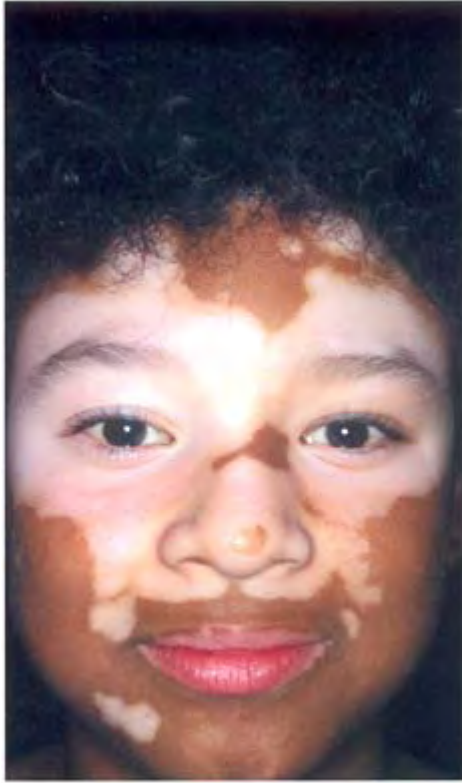**Figure 8.7** Riehl's melanosis (berloque dermatitis due to partner's cologne). DLP ID: *pigmented contact dermatitis 4455*



**Figure 8.8** Slate gray pigmentation due to 20 years' ingestion of minocycline. DLP ID: *hyperpigmentation, drug induced 4942*



**Figure 8.9** Vitiligo. DLP ID: *vitiligo 1839*

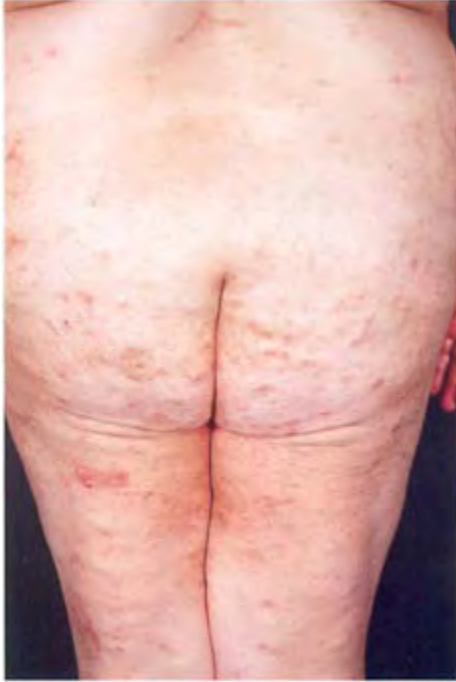

**Figure 8.10** Vitiligo. DLP ID: *vitiligo 1839*

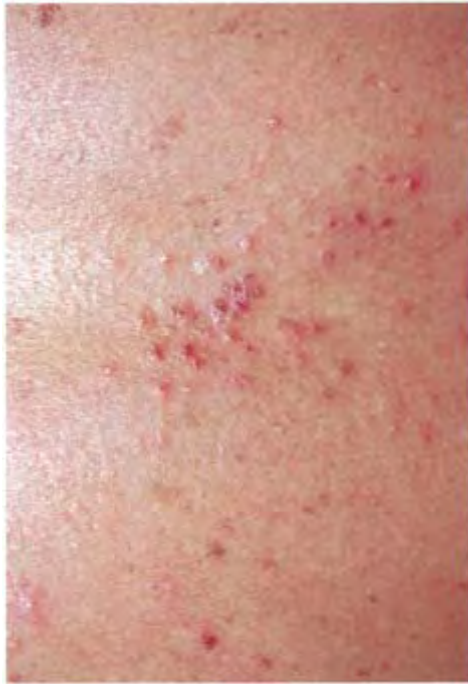

## 9

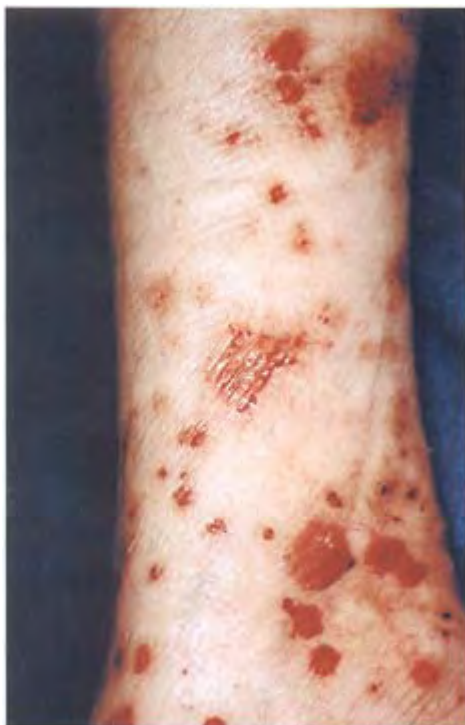### Vesicular and bullous diseases



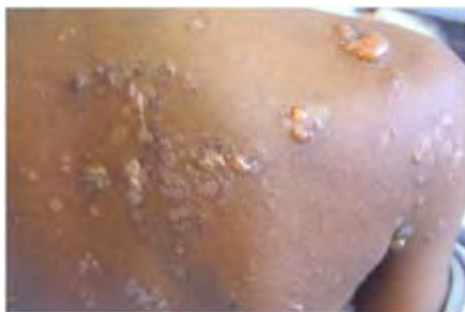**Figure 9.1** Dermatitis herpetiformis (Dühring's disease). Dermatology Lexicon Project (DLP) preferred term and number: *dermatitis herpetiformis 1764*



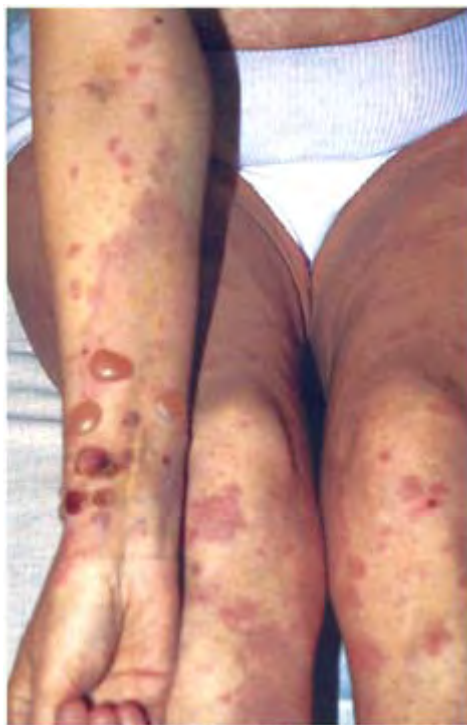**Figure 9.2** Dermatitis herpetiformis (Duhring's disease). DLP ID: *dermatitis herpetiformis 1764*



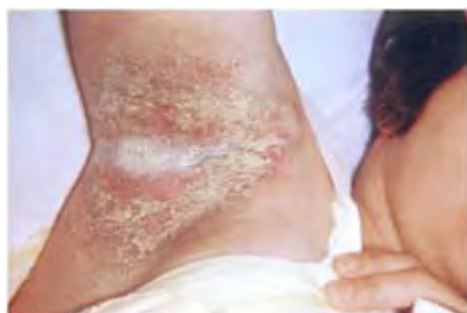**Figure 9.3** Diabetic bulla. DLP ID: *bullosis diabeticorum* 2799. Courtesy of Dr G Lestringent, Abu Dahbi, United Arab Emirates



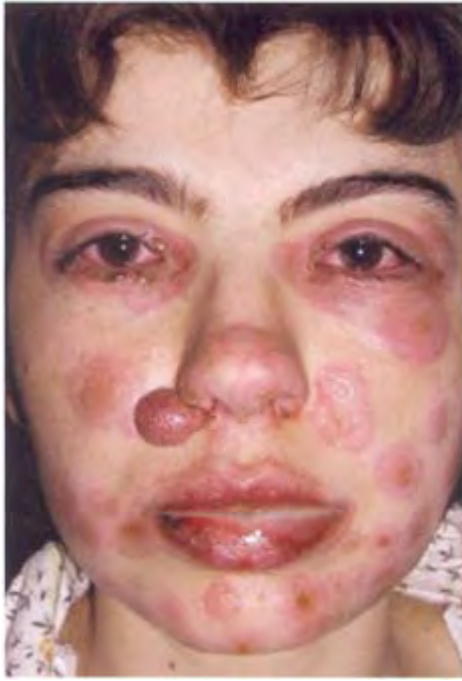**Figure 9.4** Linear IgA bullous dermatosis. DLP ID: *linear bullous dermatosis* 1765. Courtesy of Dr S Vassileva, Sofia, Bulgaria



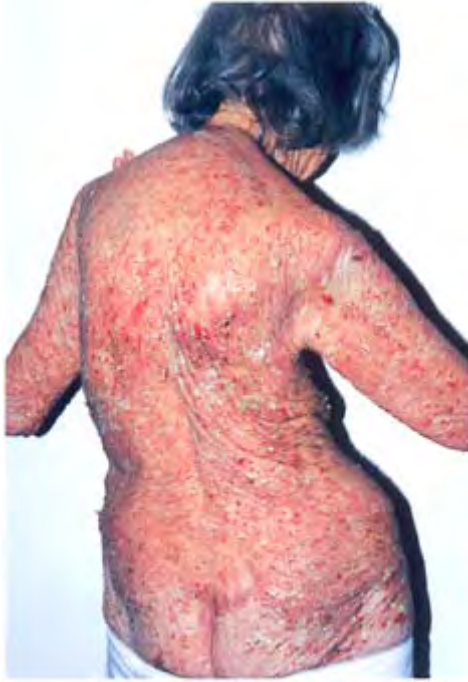**Figure 9.5** Pemphigoid, bullous. DLP  
ID: *pemphigoid, bullous 1760*



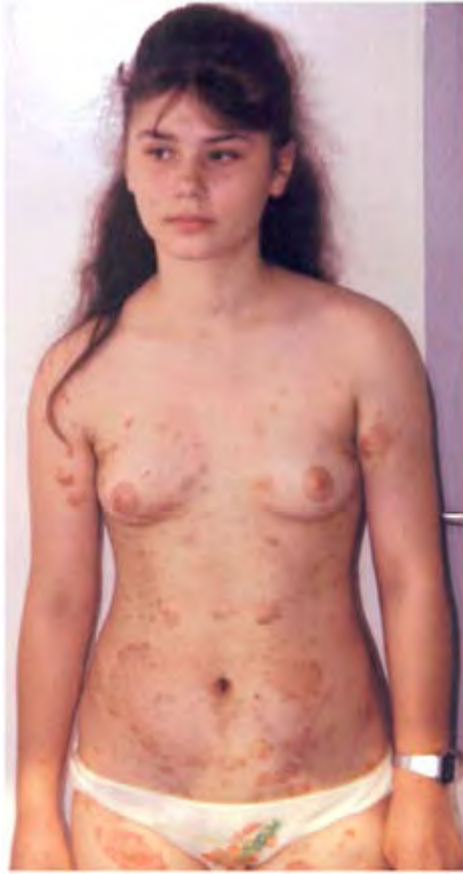**Figure 9.6** Pemphigus, benign familial chronic (Hailey-Hailey disease). DLP  
ID: *Hailey-Hailey disease 3503*



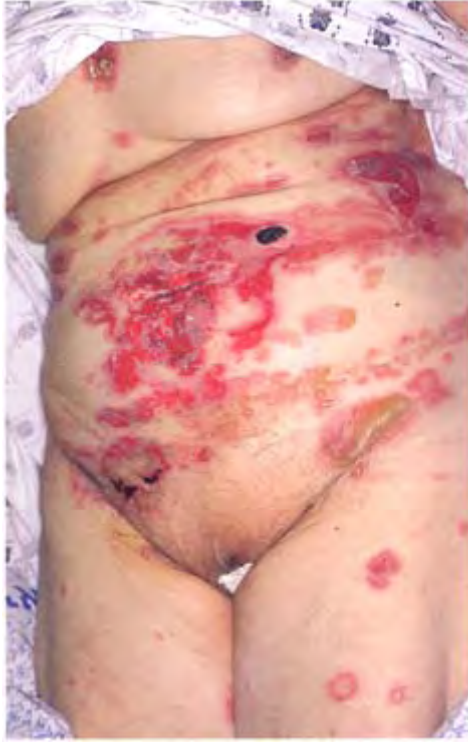**Figure 9.7** Pemphigus erythematosus (Senear Usher syndrome). DLP ID: *pemphigus erythematosus 1751*. Courtesy of Dr I Botev, Sofia, Bulgaria



**Figure 9.8** Pemphigus foliaceus. DLP  
ID: *pemphigus foliaceus 1750*

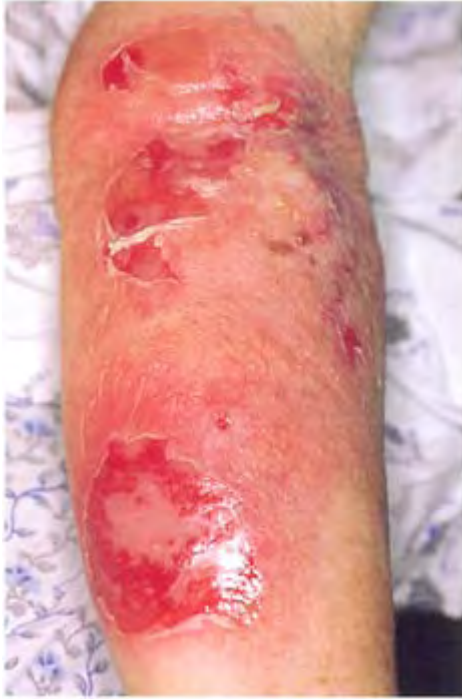

**Figure 9.9** Pemphigus herpetiformis.  
DLP ID: *pemphigus herpetiformis*  
1755

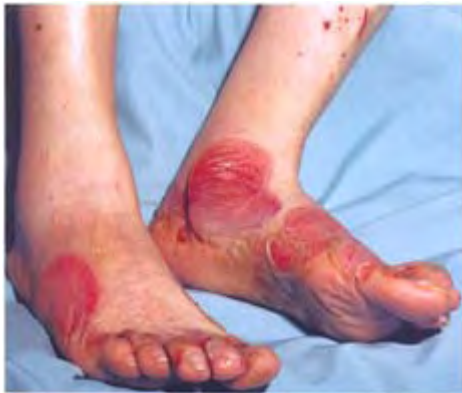

**Figure 9.10** Pemphigus vulgaris. DLP  
ID: *pemphigus vulgaris 1748*

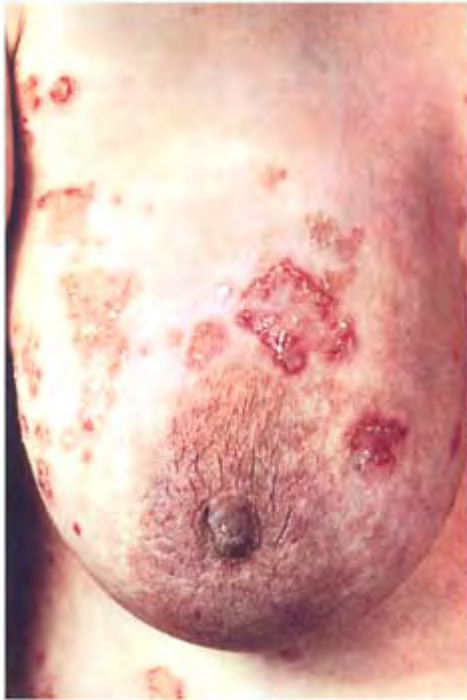



**Figure 9.11** Pemphigus vulgaris. DLP  
ID: *pemphigus vulgaris 1748*



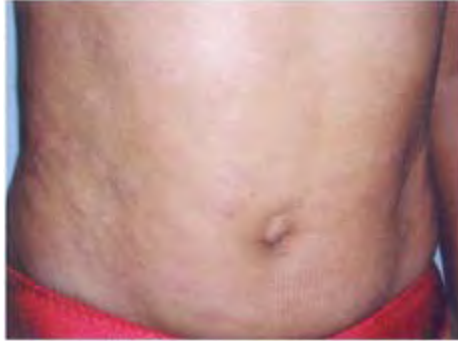**Figure 9.12** Pemphigus vulgaris. DLP  
ID: *pemphigus vulgaris 1748*



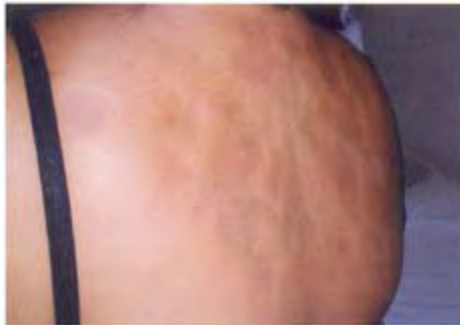**Figure 9.13** Subcorneal pustulosis of Sneddon and Wilkinson. DLP ID: *subcorneal pustular dermatosis 1769*

## 10

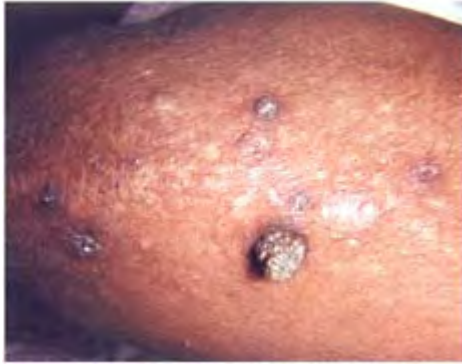### Connective tissue diseases



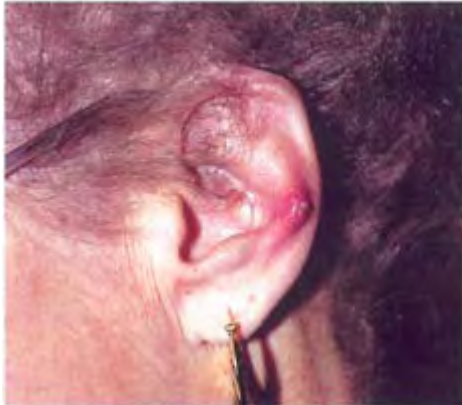**Figure 10.1** Anetoderma following secondary syphilis. Dermatology Lexicon Project (DLP) preferred term and number: *anetoderma 2241*. Courtesy of Drs N Fernandes and G Munhoz-da-Fontoura, Rio de Janeiro, Brazil



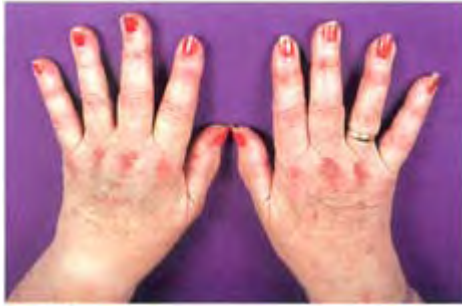**Figure 10.2** Atrophoderma of Pasini and Pierini. DLP ID: *atrophoderma of Pasini and Pierini 1823*. Courtesy of Dr G Munhoz-da-Fontoura, Rio de Janeiro, Brazil



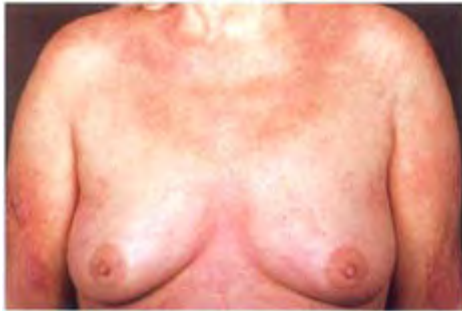**Figure 10.3** Calcinosis cutis. DLP ID:  
*calcinosis cutis 2679*



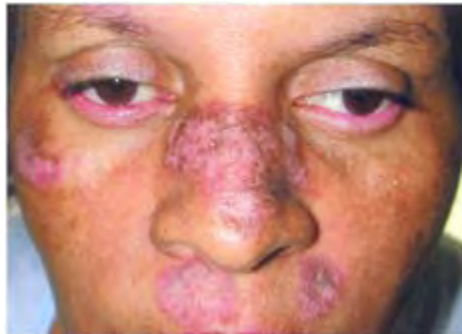**Figure 10.4** Chondrodermatitis  
nodularis helicis. DLP ID:  
*chondrodermatitis nodularis helicis  
1201*



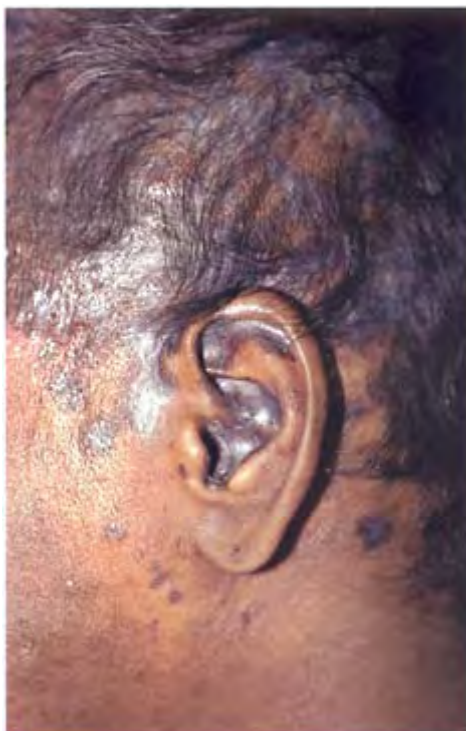**Figure 10.5** Dermatomyositis. DLP ID: *dermatomyositis 1796*



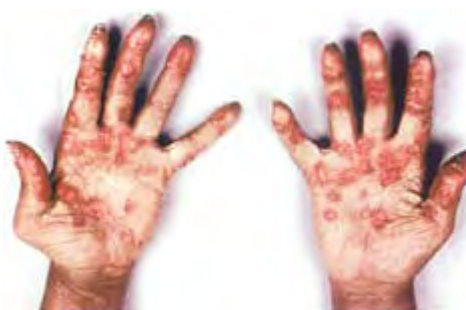**Figure 10.6** Dermatomyositis. DLP ID: *dermatomyositis 1796*



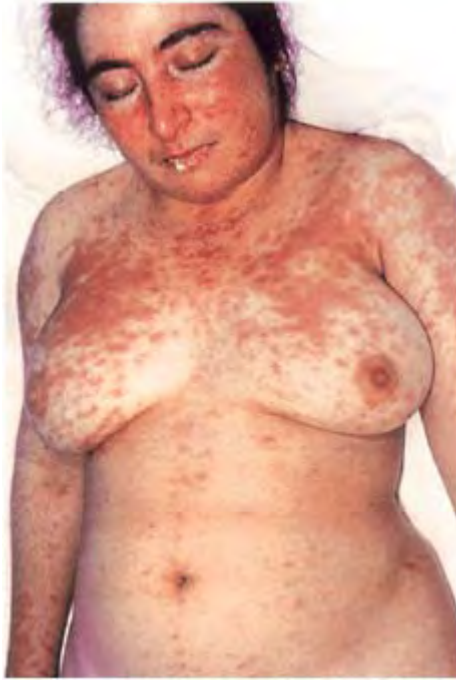**Figure 10.7** Lupus erythematosus, discoid. DLP ID: *lupus erythematosus discoid 1803*



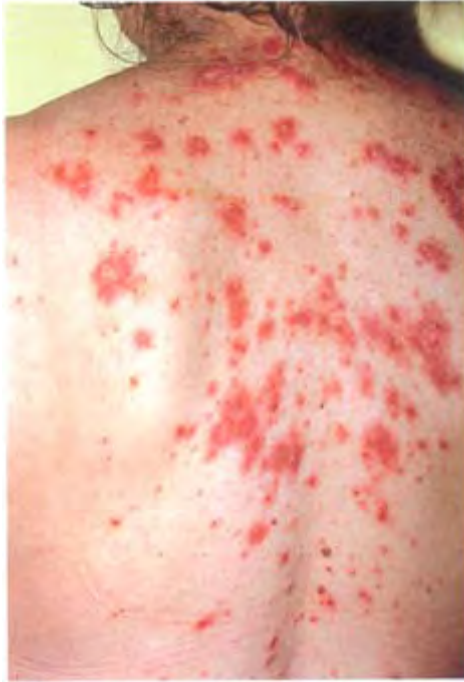**Figure 10.8** Lupus erythematosus, discoid. DLP ID: *discoid lupus erythematosus 1803*



**Figure 10.9** Lupus erythematosus, systemic. DLP ID: *systemic lupus erythematosus 1808*

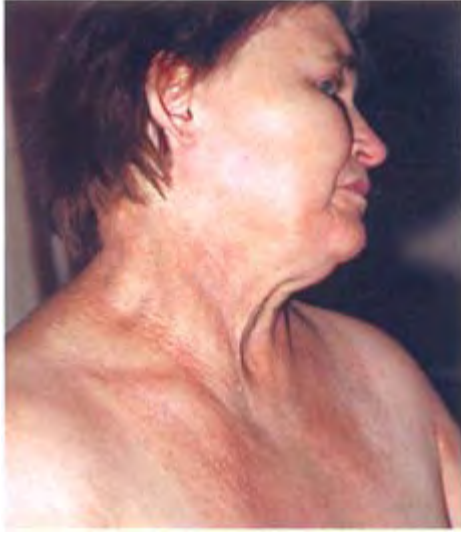

**Figure 10.10** Lupus erythematosus, systemic. DLP ID: *systemic lupus erythematosus 1808*

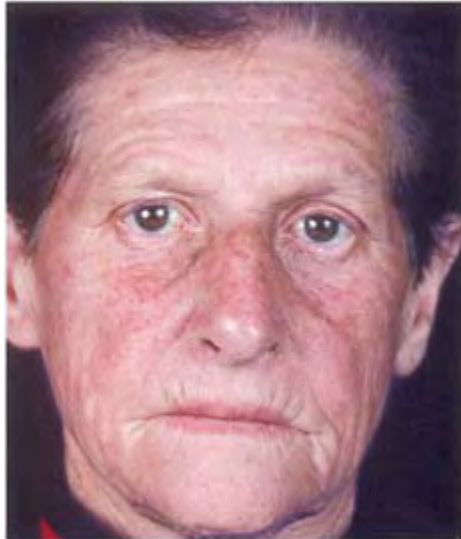

**Figure 10.11** Lupus erythematosus, systemic associated with lung cancer.  
DLP ID: *systemic lupus erythematosus*  
1808

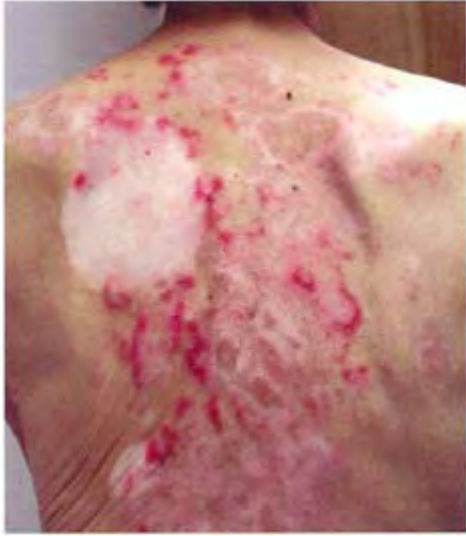



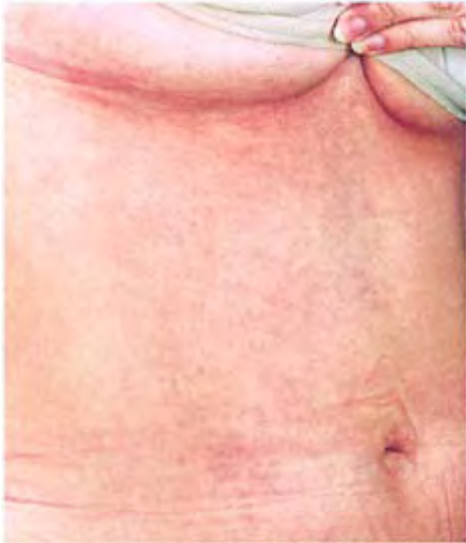**Figure 10.12** Pseudoxanthoma elasticum. DLP ID: *pseudoxanthoma elasticum 3398*



**Figure 10.13** Scleroderma. DLP ID: *scleroderma 1795*



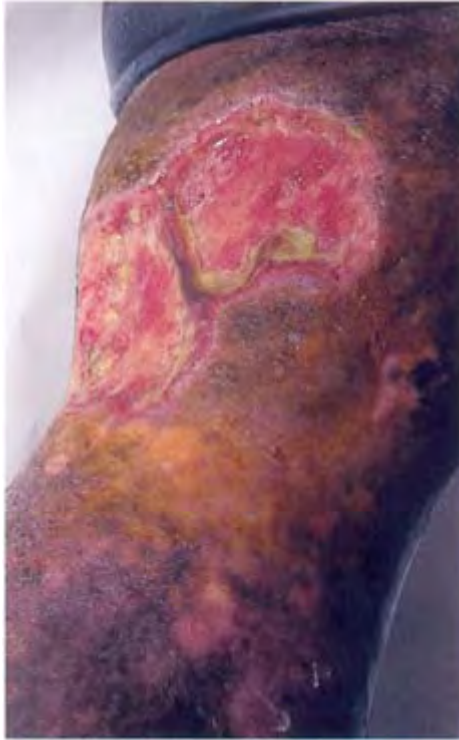**Figure 10.14** Scleroderma. DLP ID: *scleroderma 1795*



**Figure 10.15** Scleroderma, morphea. DLP ID: *morphea 1821*

# 11

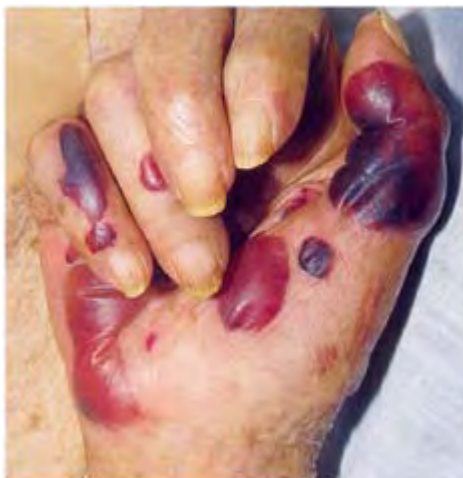## Vascular diseases



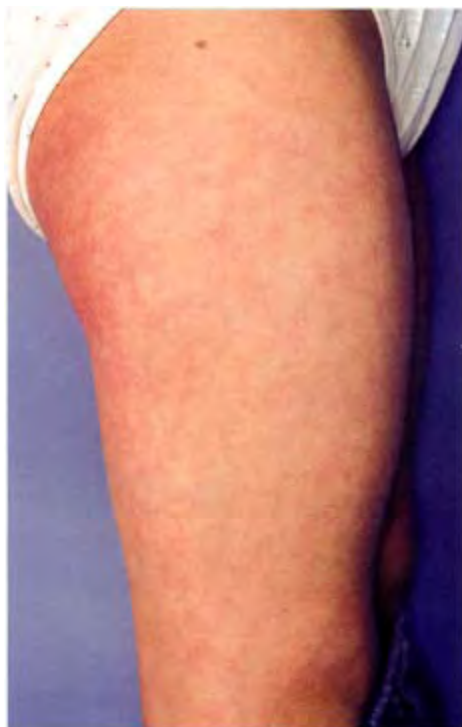**Figure 11.1** Decubitus ulcer.  
Dermatology Lexicon Project (DLP)  
preferred term and number: *decubitus  
ulcer 3853*



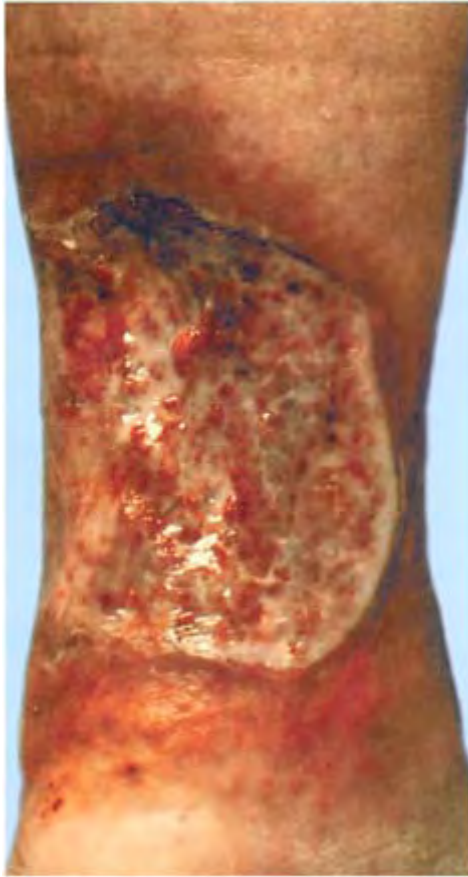**Figure 11.2** Decubitus ulcer. DLP ID: *decubitus ulcer 3853*



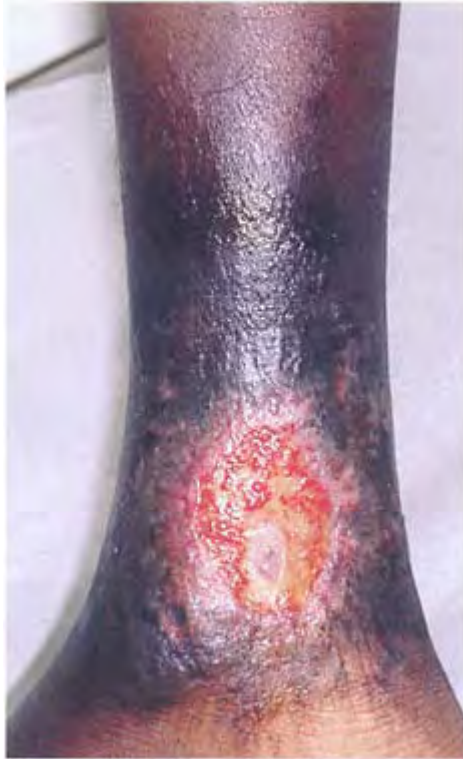**Figure 11.3** Decubitus ulcer—bullous. DLP ID: *decubitus ulcer 3853*



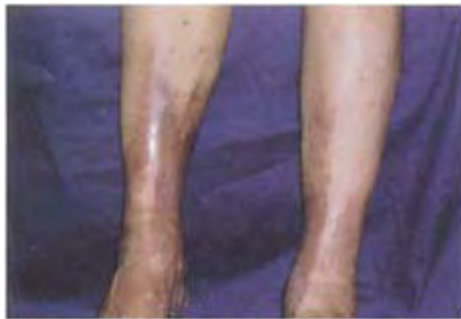**Figure 11.4** Livedo reticularis. DLP  
ID: *livedo reticularis 2441*



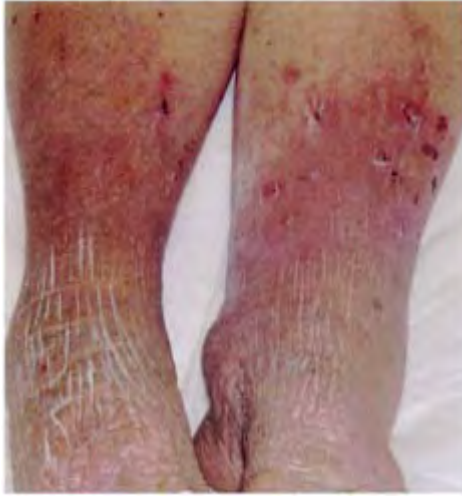**Figure 11.5** Pyoderma gangrenosum.  
DLP ID: *pyoderma gangrenosum 2164*



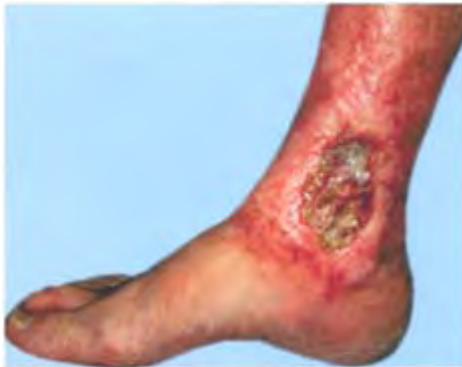**Figure 11.6** Sickle cell leg ulcer. DLP ID: *sickle cell ulcer 6695*



**Figure 11.7** Stasis dermatitis. DLP ID: *stasis dermatitis 2109*

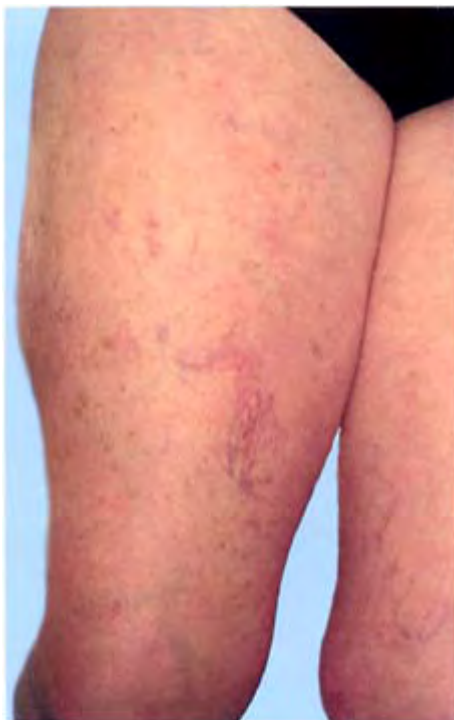

**Figure 11.8** Stasis dermatitis. DLP ID: *stasis dermatitis 2109*

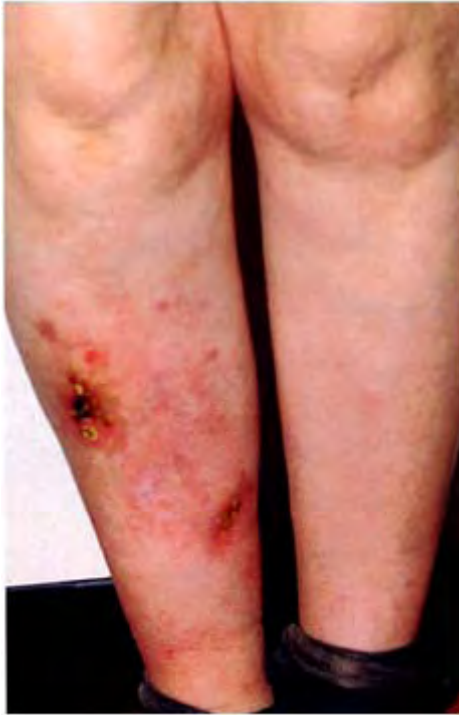

**Figure 11.9** Stasis ulcer with stasis dermatitis. DLP ID: *stasis ulcer 2514*





**Figure 11.10** Varicosities and telangiectasias. DLP ID: *varicosities* 2539



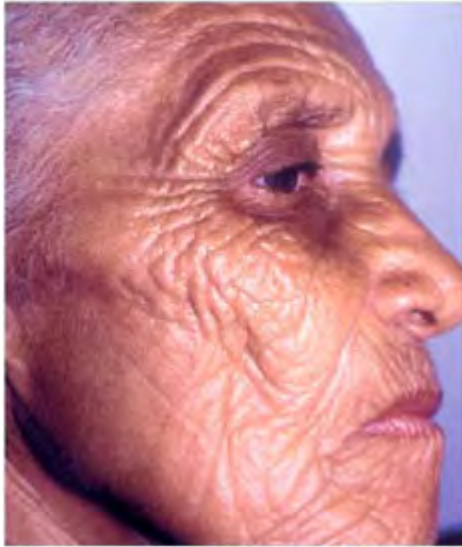**Figure 11.11** Vasculitis, necrotizing.  
DLP ID: *necrotizing vasculitis* 2858

## 12 Cutaneous tumors

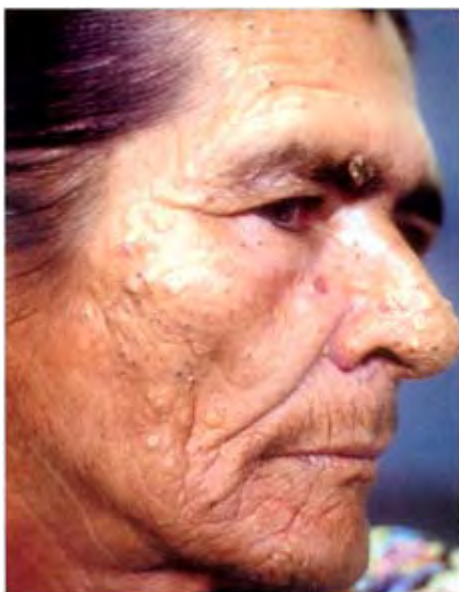### BENIGN AND PREMALIGNANT



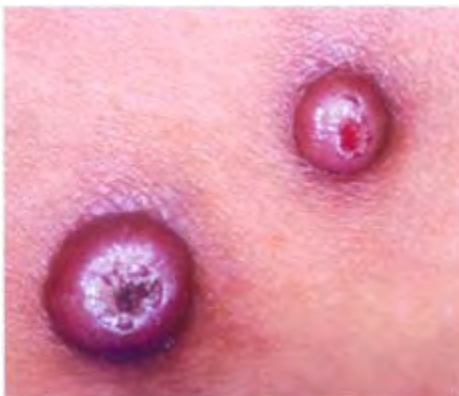**Figure 12.1** Actinic damage with seborrheic keratoses. Dermatology Lexicon Project (DLP) preferred term and number: *actinic damage 6697*



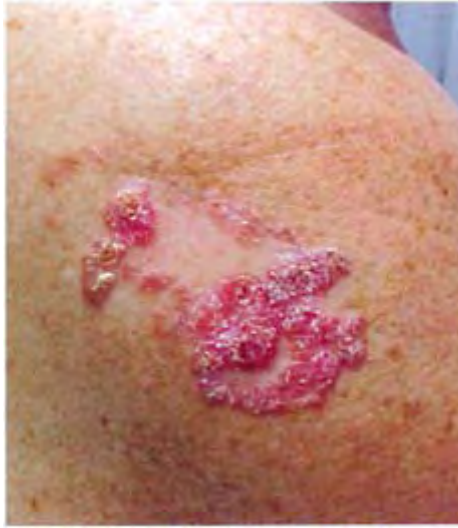**Figure 12.2** Actinic damage without seborrheic keratoses. DLP ID: *actinic damage 6697*. Courtesy of Dr T Cestari, Porto Alegre, Brazil



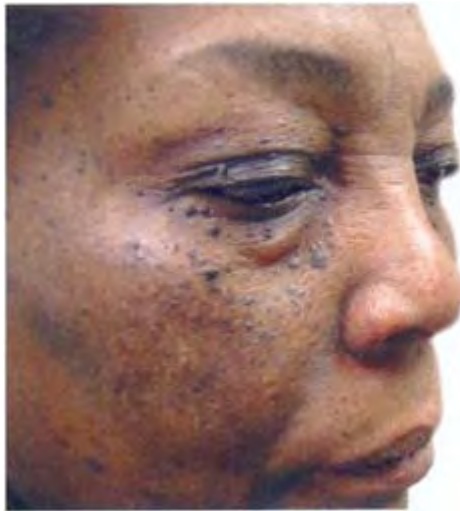**Figure 12.3** Actinic keratoses with nodular elastosis, cysts, and comedones (Favre-Racouchot syndrome). DLP ID: *actinic keratosis 775*. Courtesy of Dr T Cestari, Porto Alegre, Brazil



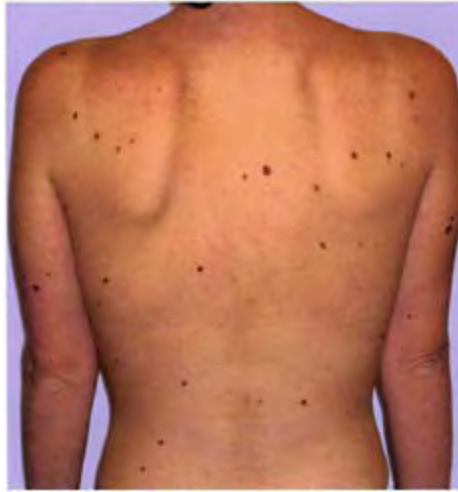**Figure 12.4** Angiolymploid hyperplasia. DLP ID: *angiolymploid hyperplasia with eosinophilia 1423*



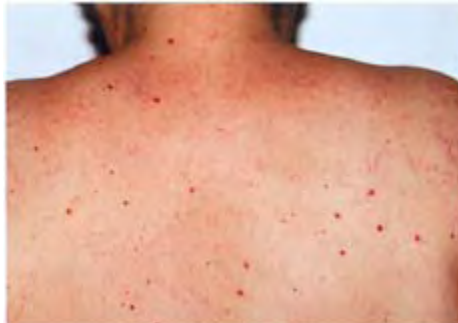**Figure 12.5** Bowen's disease (squamous cell carcinoma intraepidermal). DLP ID: *squamous cell carcinoma in-situ 788*



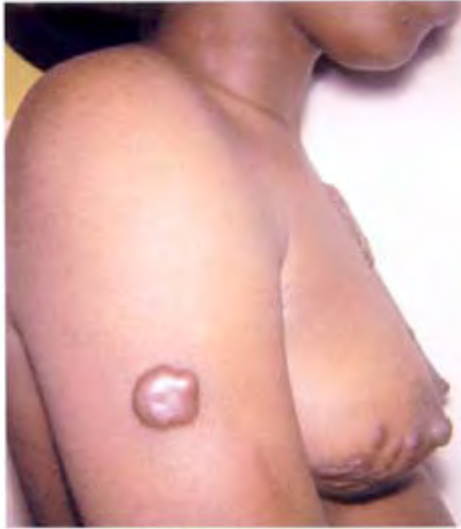**Figure 12.6** Dermatitis papulosa nigra. DLP ID: *dermatitis papulosa nigra 754*



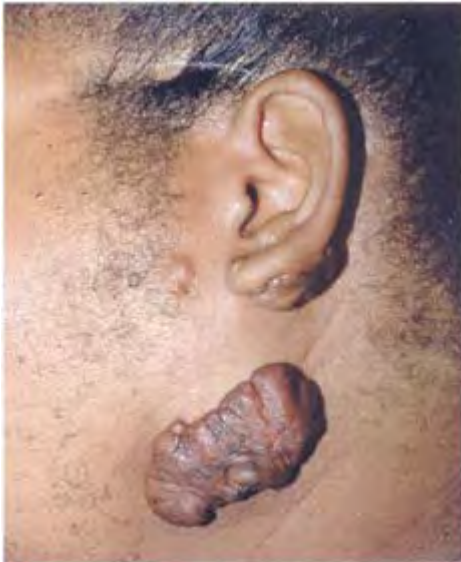**Figure 12.7** Dysplastic nevus syndrome. DLP ID: *familial atypical mole-melanoma syndrome 3229*



**Figure 12.8** Cherry angioma. DLP ID: *cherry angioma 1433*

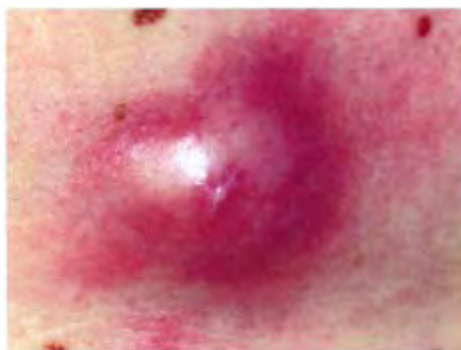

**Figure 12.9** Keloid. DLP ID: *keloid 1264*

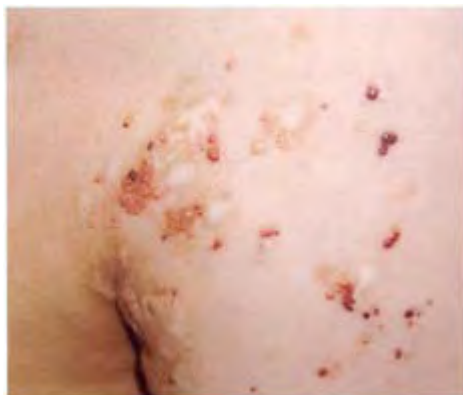

**Figure 12.10** Keloid. DLP ID: *Keloid 1264*

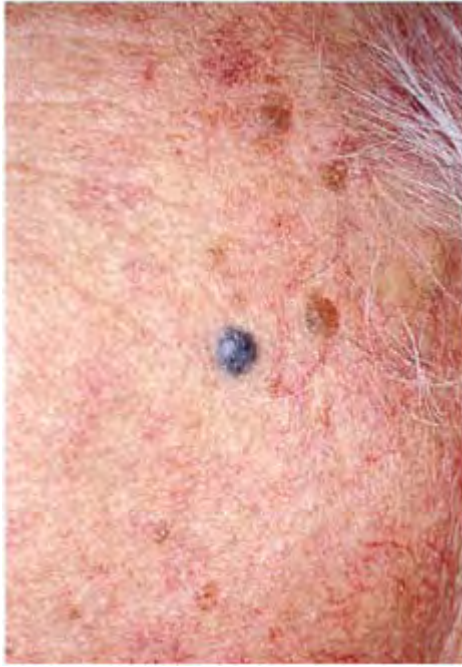



**Figure 12.11** Keratinous cyst, infected. DLP ID: *epidermoid cyst 853*



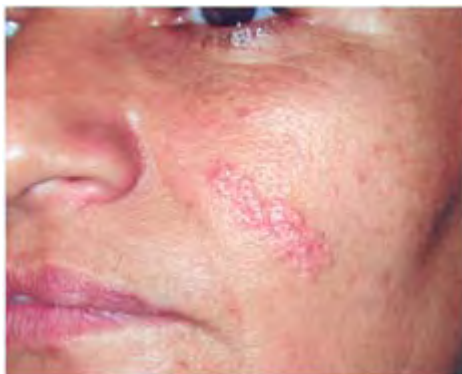**Figure 12.12** Lymphangioma circumscriptum. DLP ID: *lymphangioma circumscriptum 1477*.  
Courtesy of Dr I Botev, Sofia, Bulgaria



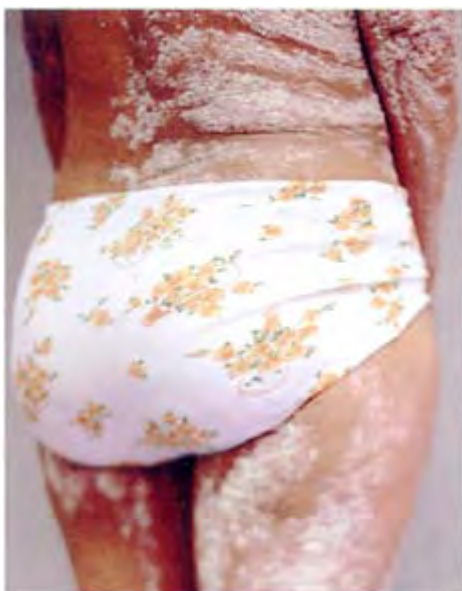**Figure 12.13** Nevus, blue of Jadassohn. DLP ID: *blue nevus 1036*



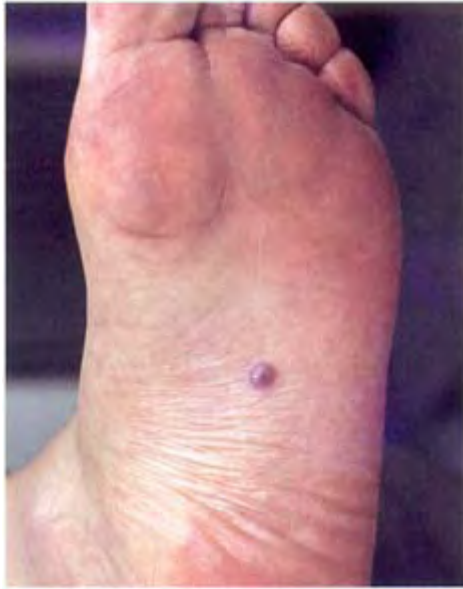**Figure 12.14** Nevus, halo of Sutton. DLP ID: *halo nevus 1014*



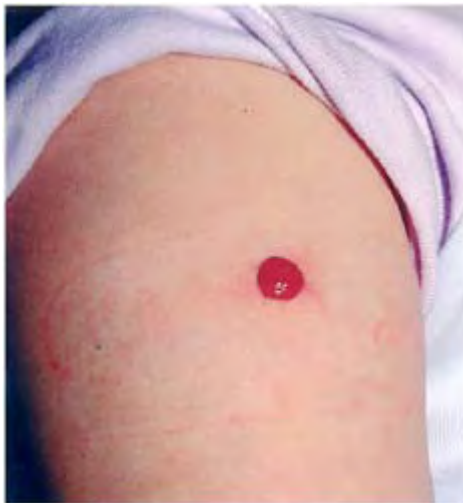**Figure 12.15** Nevus, sebaceous of Jadassohn. DLP ID: *benign sebaceous gland tumor 903*



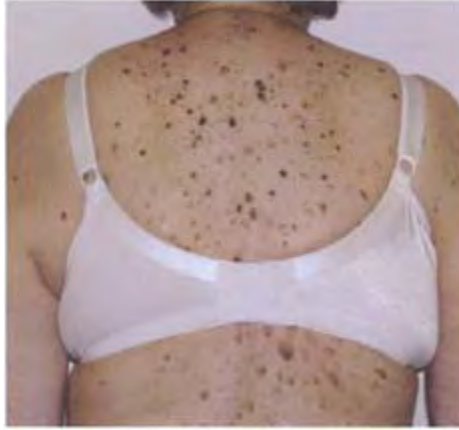**Figure 12.16** Nevus unius lateralis. DLP ID: *nevus unius lateralis 748*



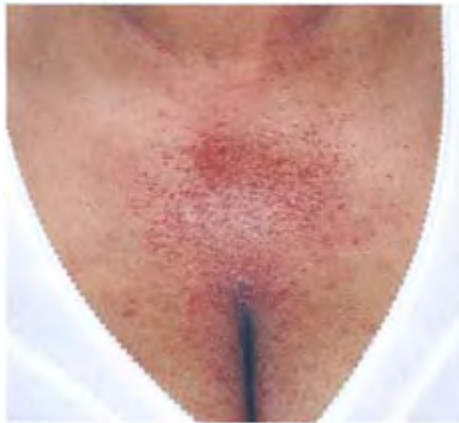**Figure 12.17** Poroma, eccrine. DLP  
ID: *eccrine poroma 935*



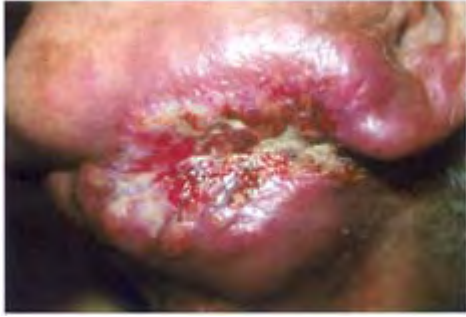**Figure 12.18** Pyogenic granuloma  
DLP ID: *pyogenic granuloma 2823*



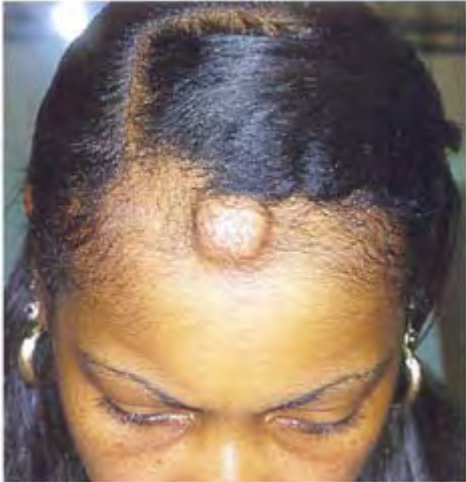**Figure 12.19** Seborrheic keratoses.  
DLP ID: *seborrheic keratoses 753*



**Figure 12.20** Steatocytoma multiplex.  
DLP ID: *steatocytoma multiplex 2885*

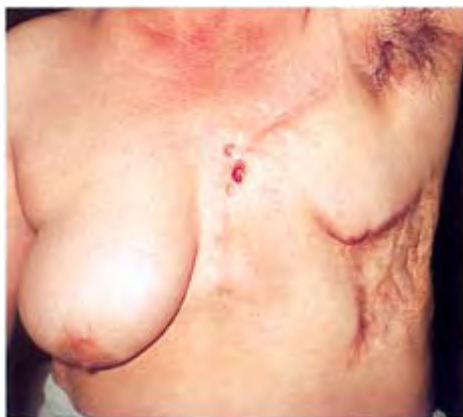

**Figure 12.21** Syringoma, chondroid (mixed tumor of the skin). DLP ID: *syringoma, chondroid 933*



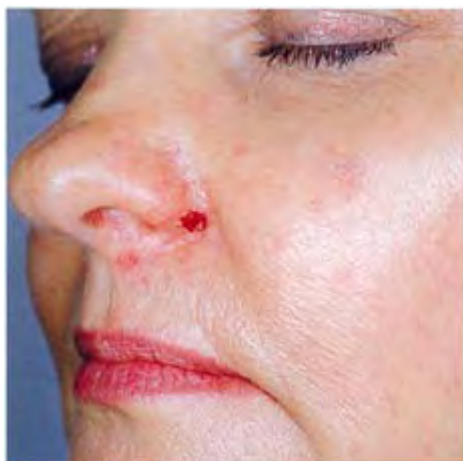**Figure 12.22** Trichilemmoma. DLP ID: *trichilemmoma 883*

**MALIGNANT**



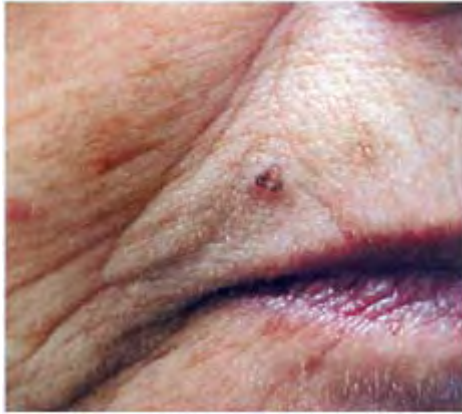**Figure 12.23** Adenocarcinoma of the breast, metastatic, post-mastectomy.

DLP ID: *metastatic breast adenocarcinoma 1676*

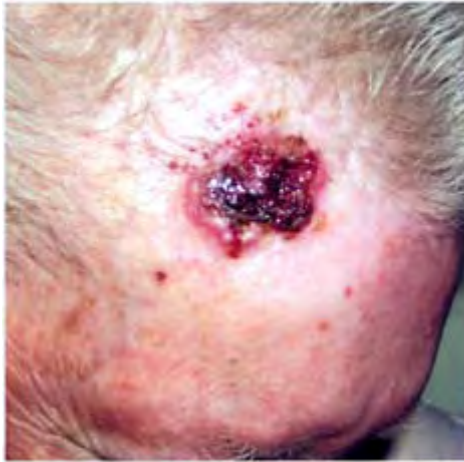

**Figure 12.24** Basal cell carcinoma.

DLP ID: *basal cell carcinoma 797*

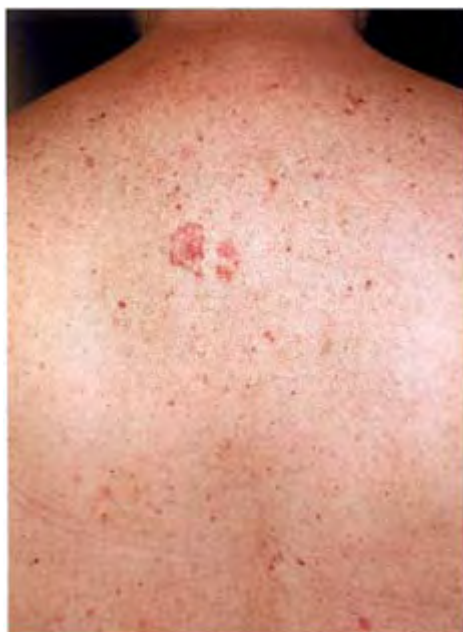

**Figure 12.25** Basal cell carcinoma.  
DLP ID: *basal cell carcinoma 797*.  
Courtesy of Dr T Cestari, Porto  
Alegre, Brazil

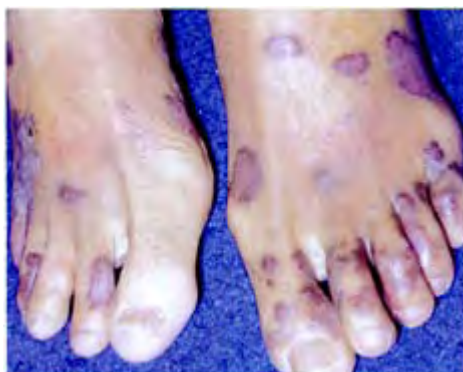

**Figure 12.26** Basal cell carcinoma  
(rodent ulcer). DLP ID: *rodent ulcer of  
basal cell carcinoma 5222*. Courtesy  
of Dr T Cestari, Porto Alegre, Brazil

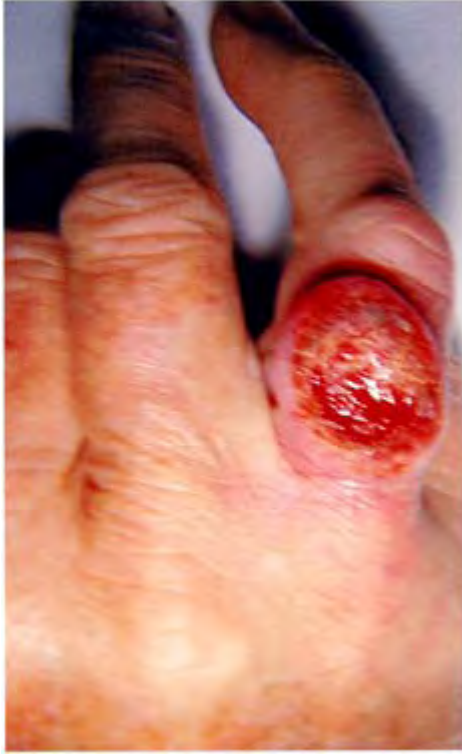



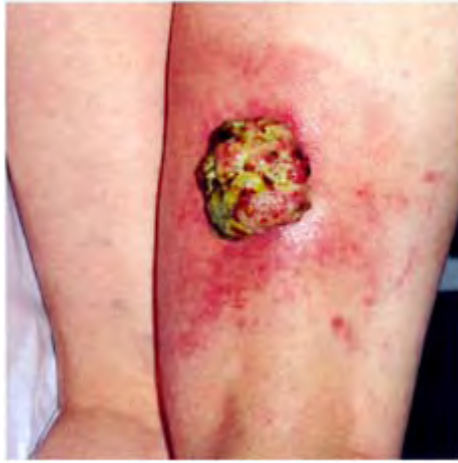**Figure 12.27** Basal cell nevus syndrome. DLP ID: *basal cell nevus syndrome 2883*



**Figure 12.28** Kaposi's sarcoma in an immunocompetent patient. DLP ID: *Kaposi sarcoma 1457*. Courtesy of Drs L Guedes and G Munhoz-da-Fontoura, Rio de Janeiro, Brazil



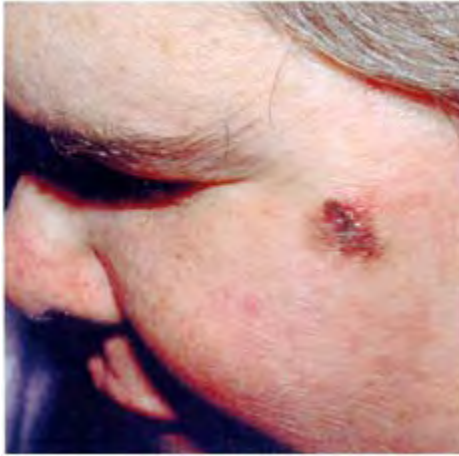**Figure 12.29** Keratoacanthoma. DLP  
ID: *keratoacanthoma 747*



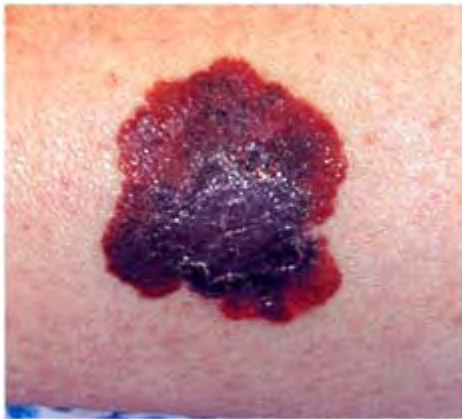**Figure 12.30** Melanoma, amelanotic.  
DLP ID: *melanoma, amelanotic 1068*



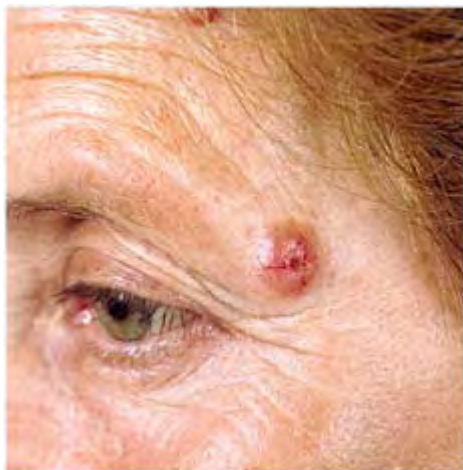**Figure 12.31** Melanoma, level 1  
within a tattoo. DLP ID: *malignant melanoma 4758*



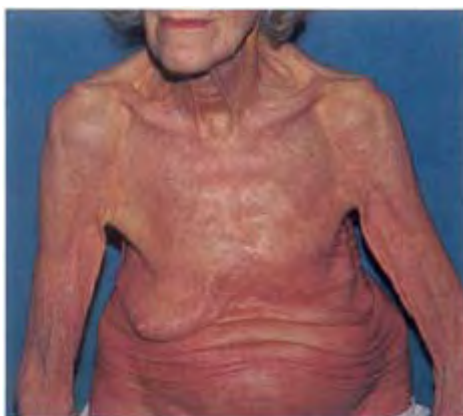**Figure 12.32** Melanoma, level 2. DLP  
ID: *malignant melanoma 4758*



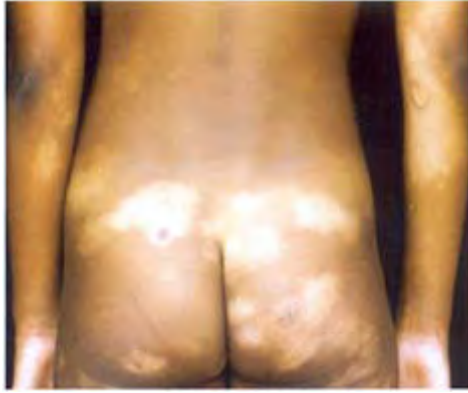
**Figure 12.33** Melanoma, level 4. DLP  
ID: *malignant melanoma 4758*



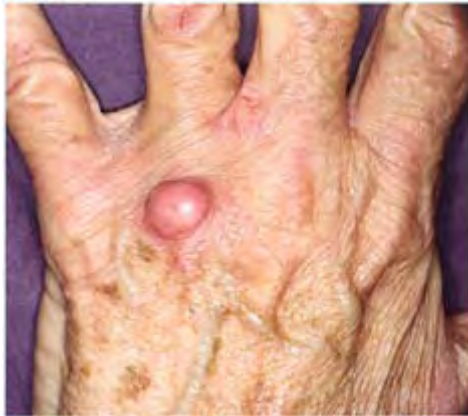**Figure 12.34** Merkel cell carcinoma.  
DLP ID: *Merkel cell carcinoma 1137*



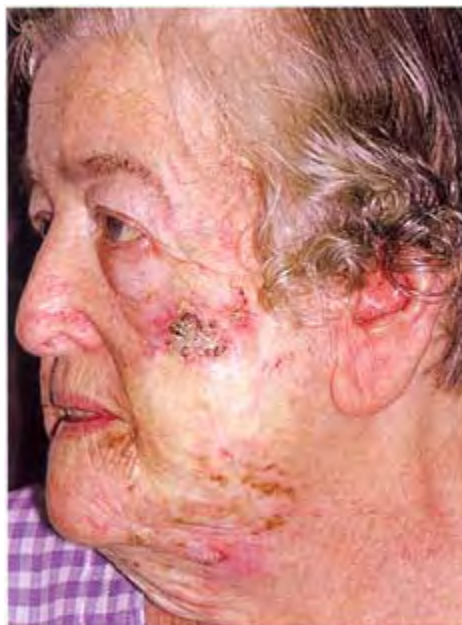**Figure 12.35** Mycosis fungoides,  
erythrodermic (cutaneous T cell  
lymphoma). DLP ID: *erythrodermic  
mycosis fungoides 1544*



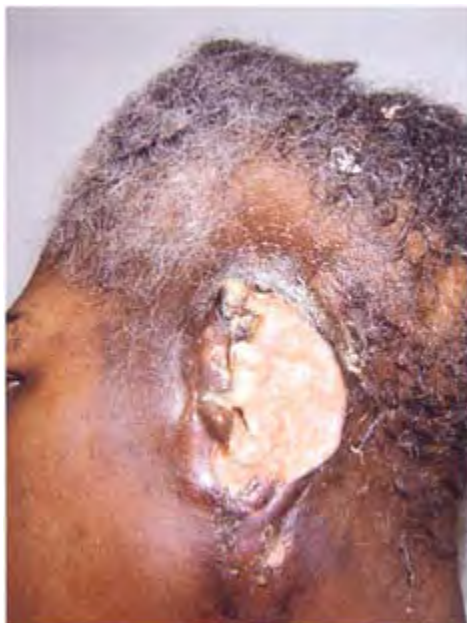**Figure 12.36** Mycosis fungoides, hypopigmented (cutaneous T cell lymphoma). DLP ID: *hypopigmented mycosis fungoides 2813*. Courtesy of Dr S Carneiro, Rio de Janeiro, Brazil



**Figure 12.37** Squamous cell carcinoma. DLP ID: *squamous cell carcinoma 798*



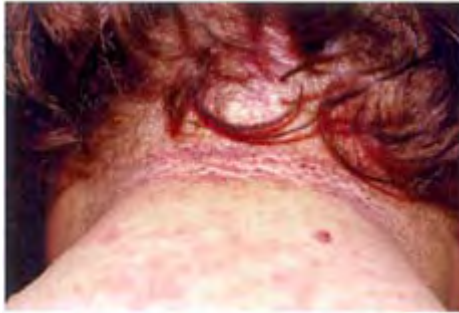**Figure 12.38** Squamous cell carcinoma. DLP ID: *squamous cell carcinoma 798*



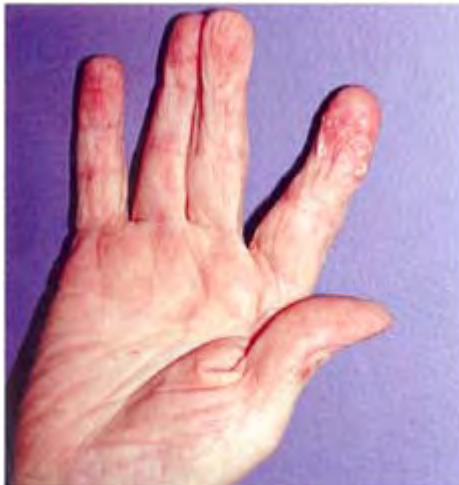**Figure 12.39** Squamous cell carcinoma. DLP ID: *squamous cell carcinoma 798*



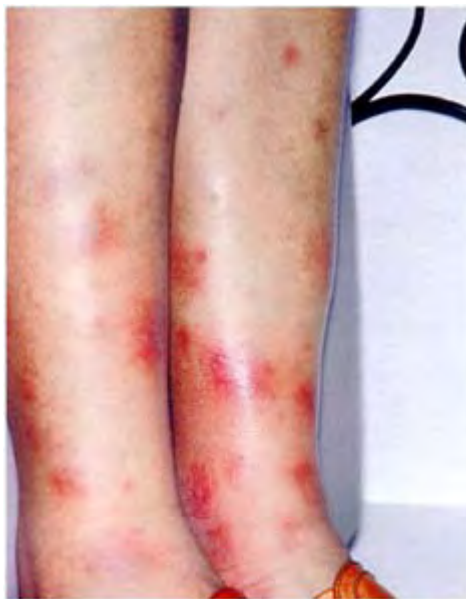**13**  
**Cutaneous manifestations of systemic  
diseases**



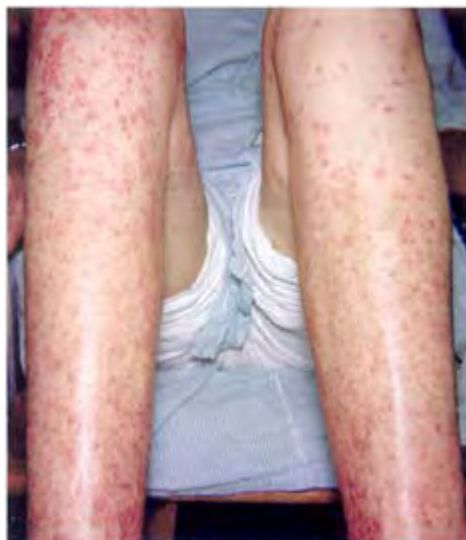**Figure 13.1** Acanthosis nigricans.  
Dermatology Lexicon Project (DLP)  
preferred term and number: *acanthosis  
nigricans 2797*



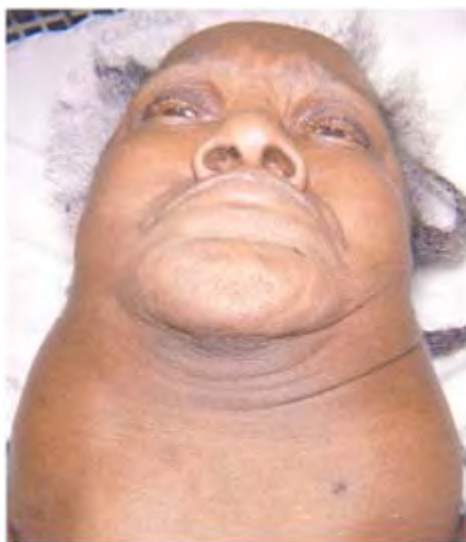**Figure 13.3** Gout. DLP ID: *gout 2594*



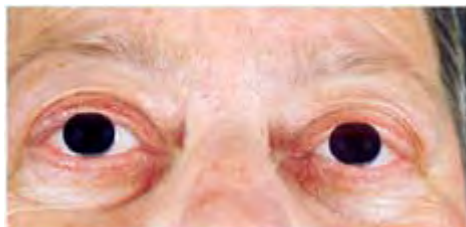**Figure 13.2** Erythema nodosum. DLP ID: *erythema nodosum 2353*



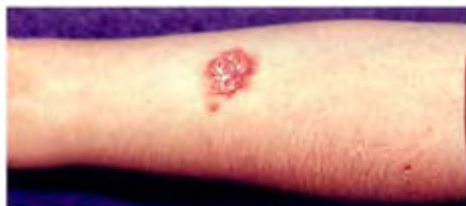**Figure 13.4**  
Hypergammaglobulinemia. DLP ID:  
*Waldenstrom macroglobulinemia 1802*



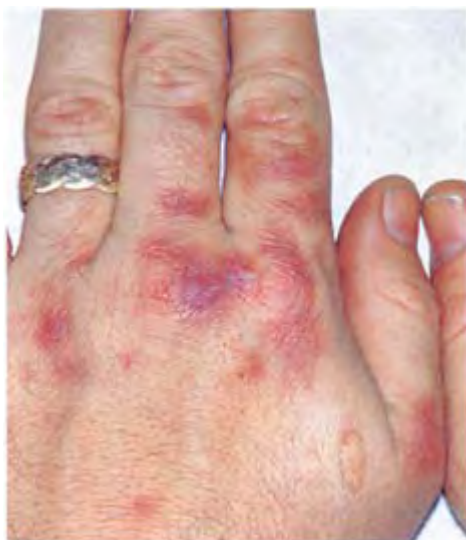**Figure 13.5** Hyperthyroidism—goiter.  
DLP ID: *hyperthyroidism goiter 1842*



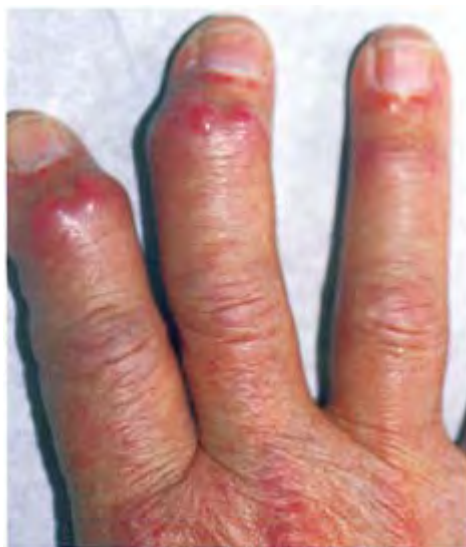**Figure 13.6** Hypothyroidism. DLP ID:  
*hypothyroidism 1843*



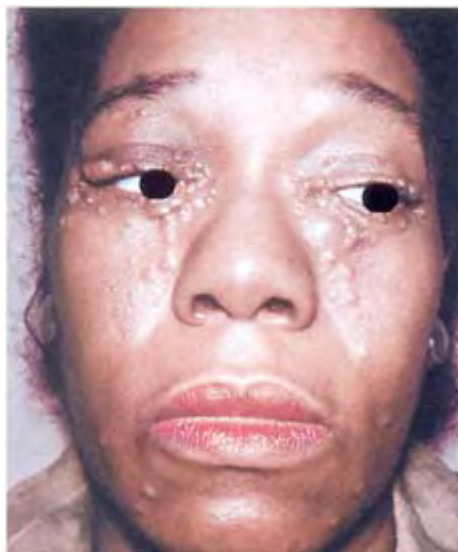**Figure 13.7** Necrobiosis lipoidica  
diabeticorum. DLP ID: *necrobiosis  
lipoidica diabeticorum 2197*



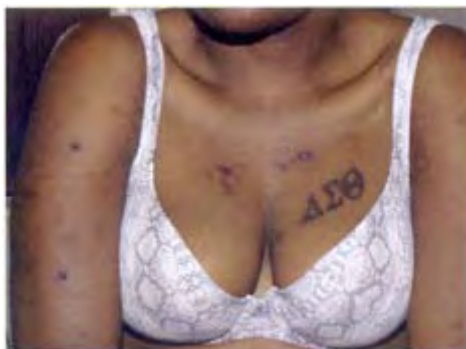**Figure 13.8** Porphyria cutanea tarda.  
DLP ID: *porphyria cutanea tarda*  
2575



**Figure 13.9** Reticulohistiocytosis,  
multicentric. DLP ID:  
*reticulohistiocytosis, multicentric* 4383



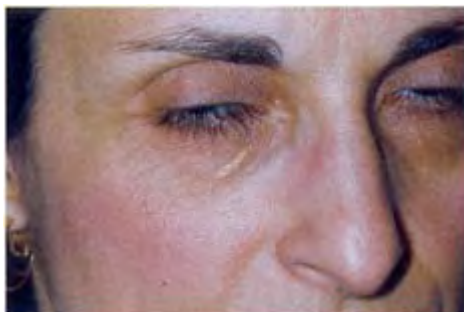**Figure 13.10** Sarcoidosis. DLP ID: *sarcoidosis 2203*



**Figure 13.11** Sarcoidosis. DLP ID: *sarcoidosis 2203*



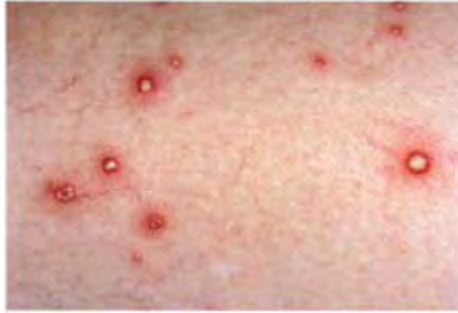**Figure 13.12** Sarcoidosis. DLP ID:  
*sarcoidosis 2203*



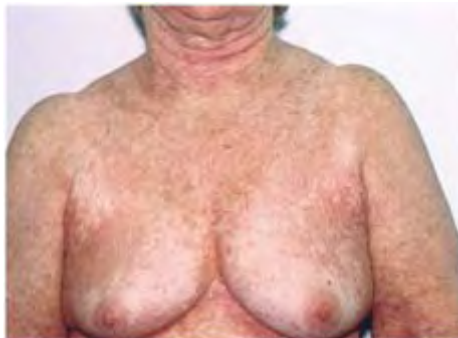**Figure 13.13** Xanthelasma. DLP ID:  
*xanthelasma 1610*

## 14

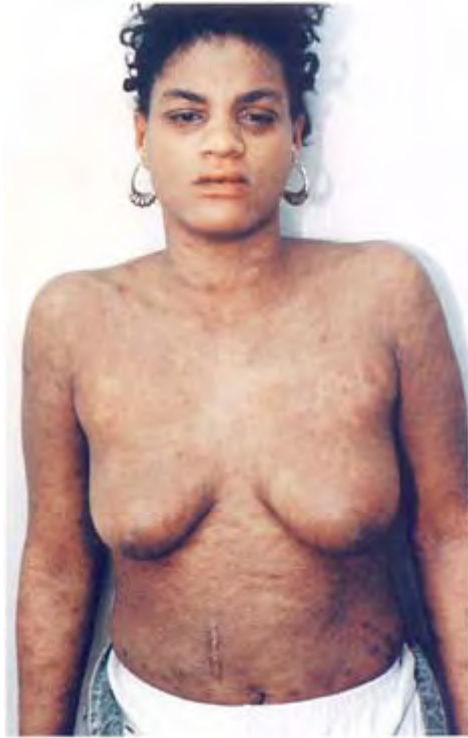### Drug eruptions



**Figure 14.1** Acute generalized exanthematous pustulosis (AGEP) due to acetaminophen (paracetamol). Dermatology Lexicon Project (DLP) preferred term and number: *acute generalized exanthematous pustulosis 1894*

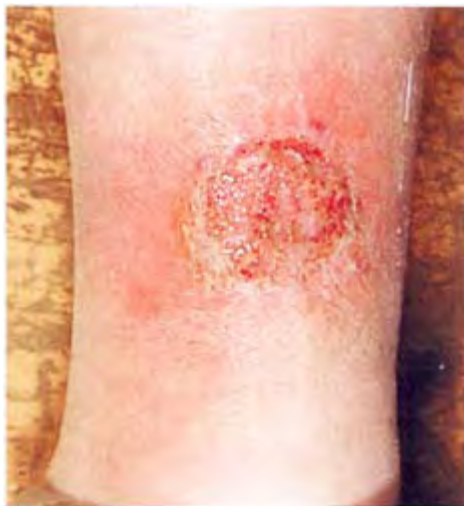

**Figure 14.2** Allergic reaction to acetylsalicylic acid. DLP ID: *exanthematous drug eruption 1889*

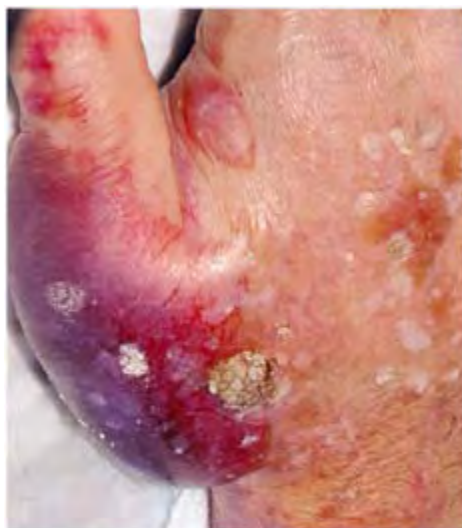

**Figure 14.3** Allergic reaction to ampicillin. DLP ID: *exanthematous drug eruption 1889*

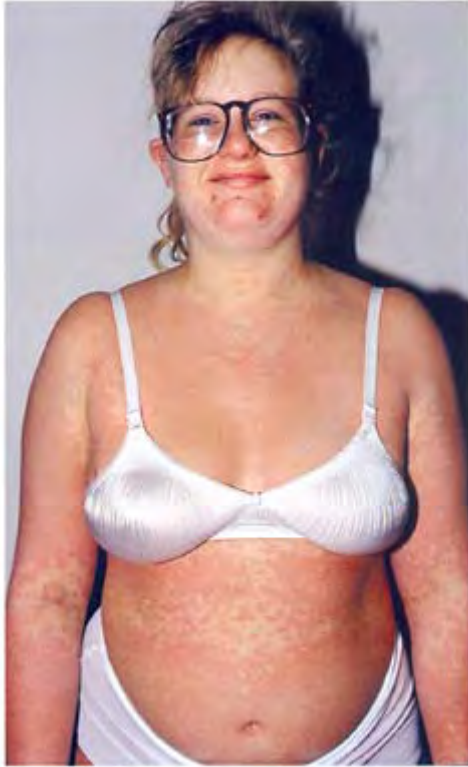



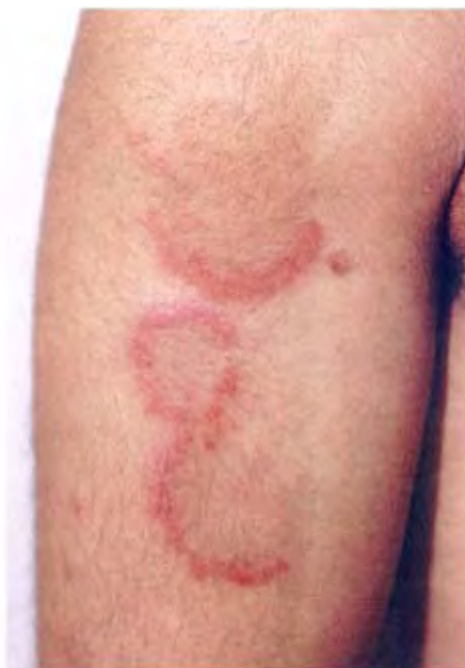**Figure 14.4** Allergic reaction to bromide (bromoderma) (originally included in Bromo-Seltzer<sup>®</sup>). DLP ID: *exanthematous drug eruption 1889*



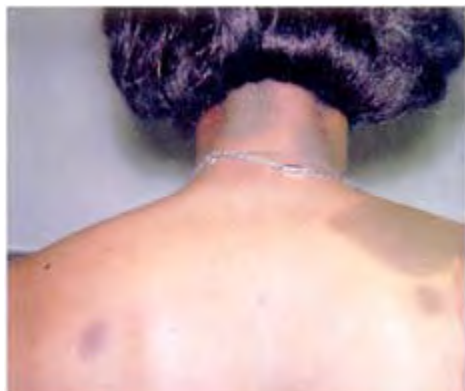**Figure 14.5** Allergic reaction to penicillin (bullous eruption from an intravenous infusion). DLP ID: *exanthematous drug eruption 1889*



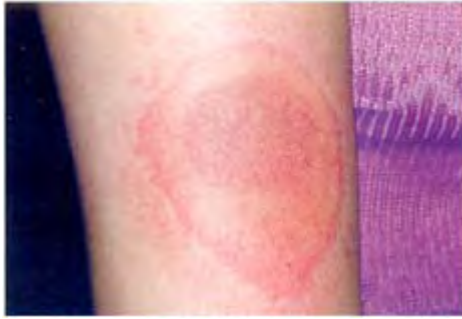**Figure 14.6** Allergic reaction to sulfonamide. DLP ID: *exanthematous drug eruption 1889*



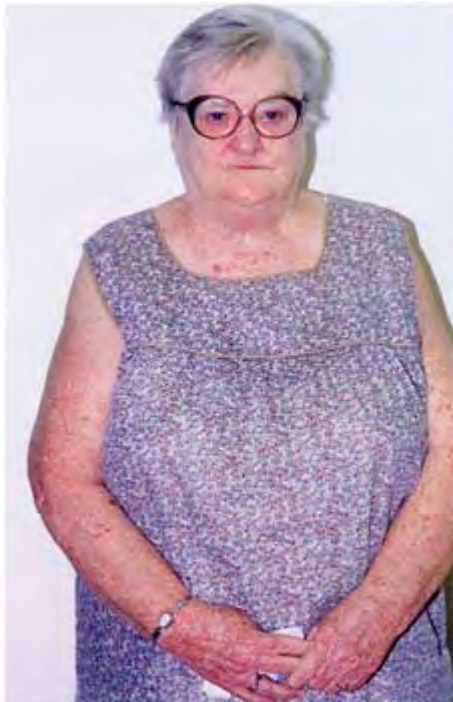**Figure 14.7** Erythema multiforme-like drug eruption to acetylsalicylic acid. DLP ID: *erythema multiforme minor 4189*



**Figure 14.8** Fixed drug eruption due to phenolphthalein (FDE). DLP ID: *fixed drug eruption 1887*

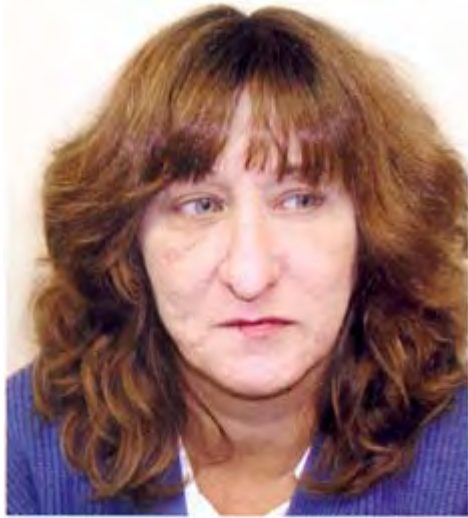

**Figure 14.9** Fixed drug eruption due to tetracycline, pulsating (PFDE). DLP ID: *fixed drug eruption 1887*

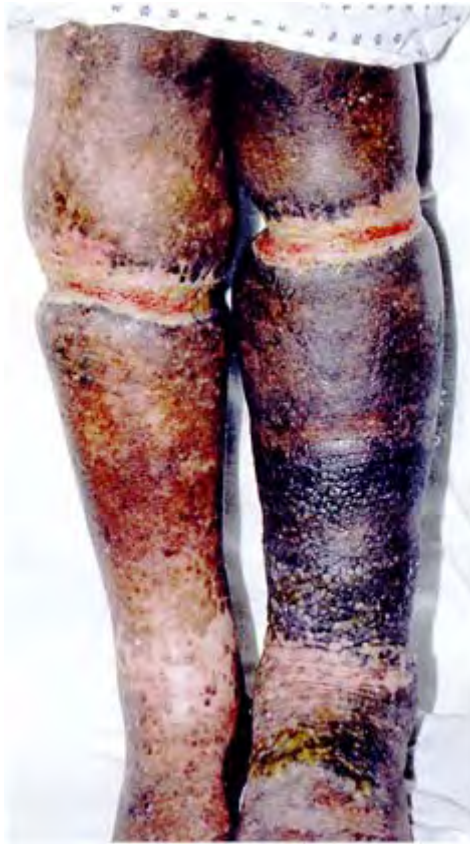

**Figure 14.10** Phototoxic drug eruption due to hydrochlorothiazide. DLP ID: *phototoxic reaction, drug induced 4181*

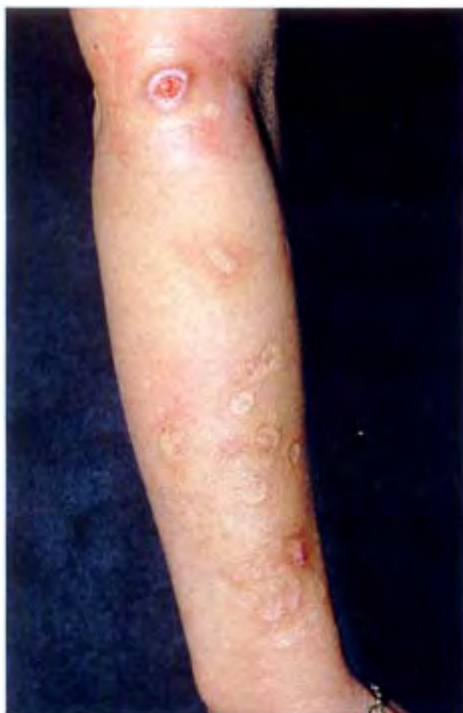## 15 Psychodermatology



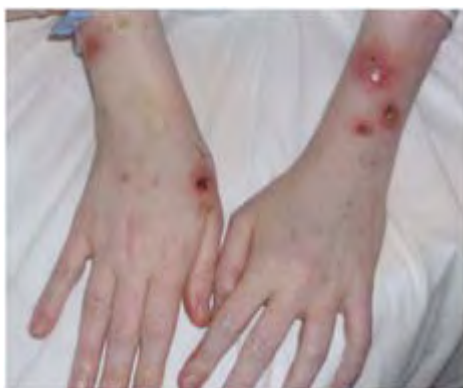**Figure 15.1** Acne excoriée and factitial dermatitis. Dermatology Lexicon Project (DLP) preferred term and number: *acne excoriee 653*



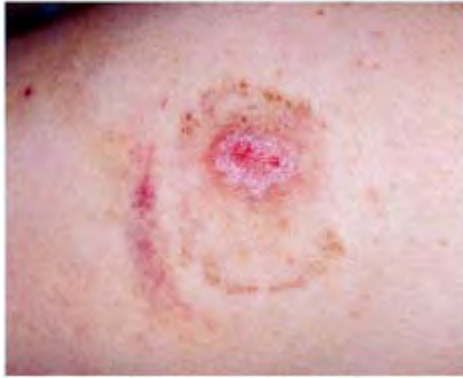**Figure 15.2** Factitial dermatitis. DLP  
ID: *dermatitis artefacta 617*



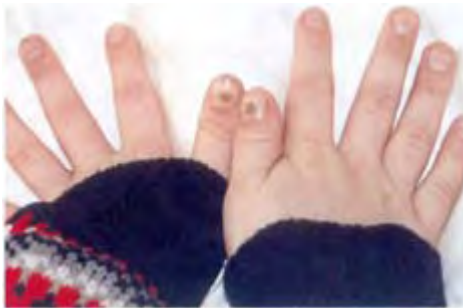**Figure 15.3** Factitial dermatitis. DLP  
ID: *dermatitis artefacta 617*



**Figure 15.4** Factitial dermatitis. DLP  
ID: *dermatitis artefacta 617*

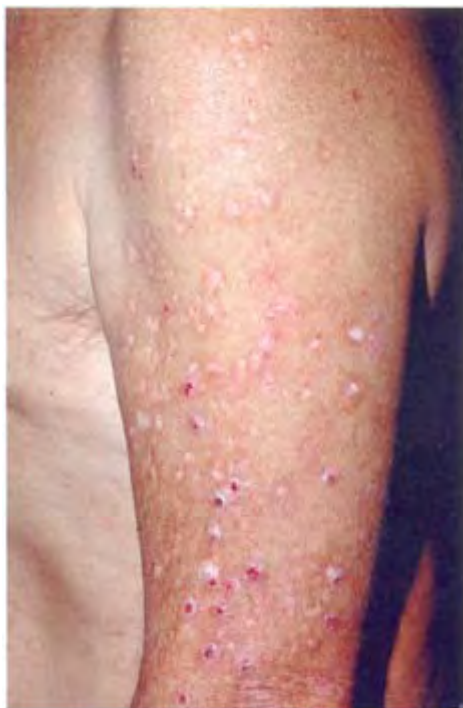

**Figure 15.5** Human bite due to spousal abuse. DLP ID: *adult physical abuse 3875*

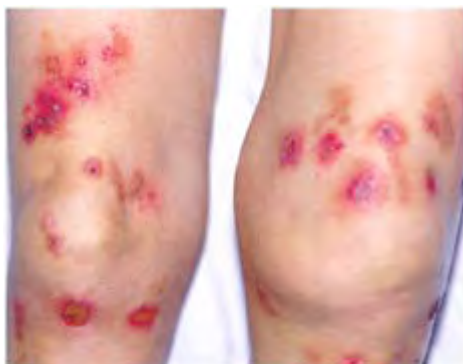

**Figure 15.6** Nail dystrophy, median (picker's nail). DLP ID: *median nail dystrophy 4801*

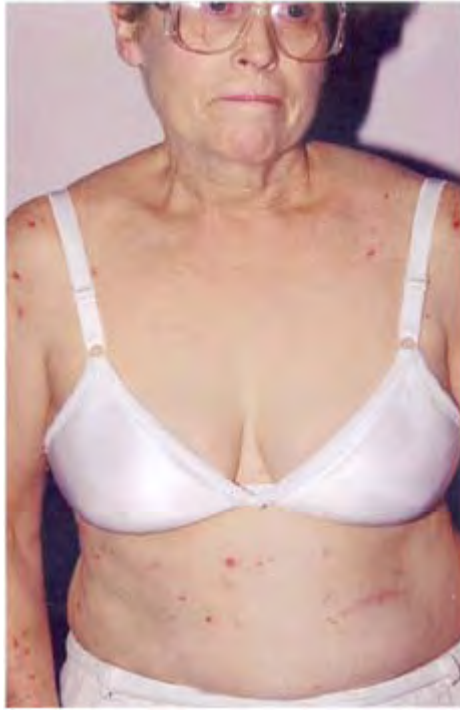




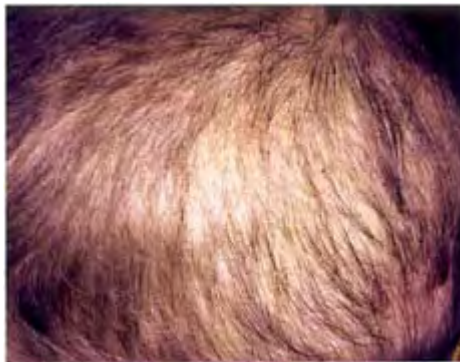**Figure 15.7** Neurotic excoriations.  
DLP ID: *dermatitis artefacta 617*



**Figure 15.8** Neurotic excoriations.  
DLP ID: *dermatitis artefacta 617*



**Figure 15.9** Parasitophobia. DLP ID: *delusion of parasitosis 689*



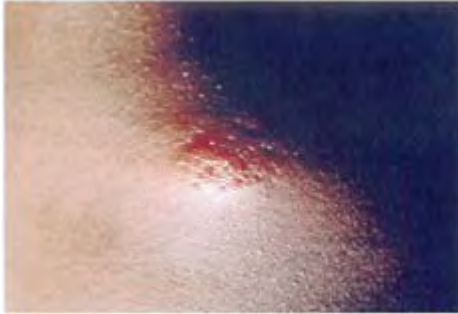
**Figure 15.10** Trichotillomania. DLP ID: *trichotillomania 656*

# Infections and infestations

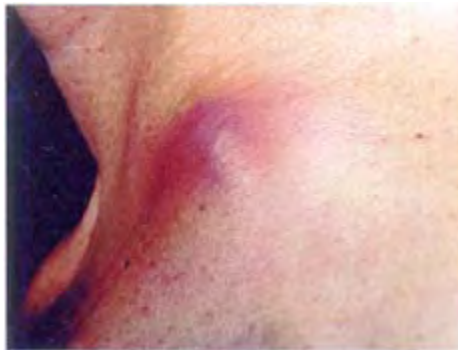## 16

# Bacterial and mycobacterial diseases

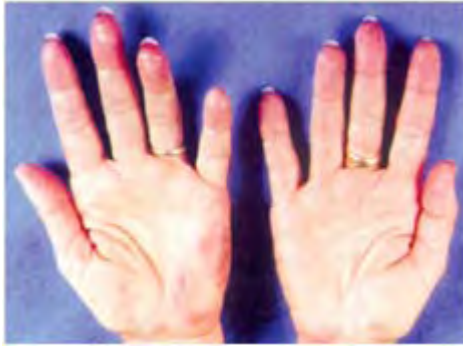### BACTERIAL



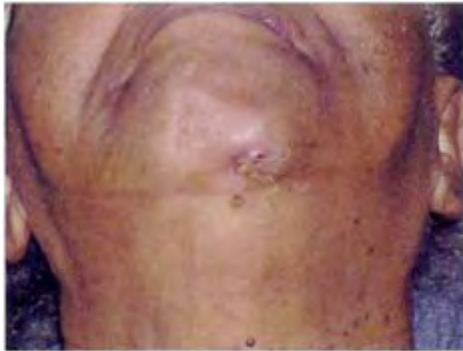**Figure 16.1** Anthrax (malignant pustule). Dermatology Lexicon Project (DLP) preferred term and number: *cutaneous anthrax 109*. Courtesy of Dr W Höffler, Tübingen, Germany



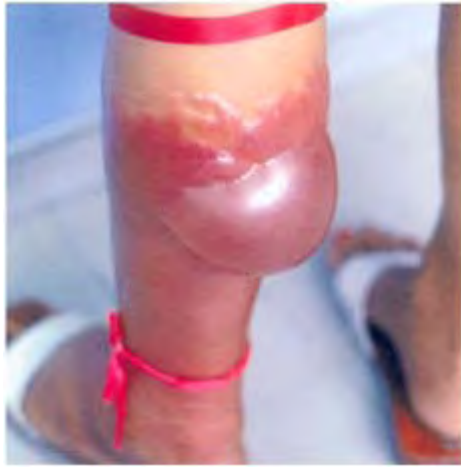**Figure 16.2** Cat scratch disease. DLP ID: *cat scratch disease 124*



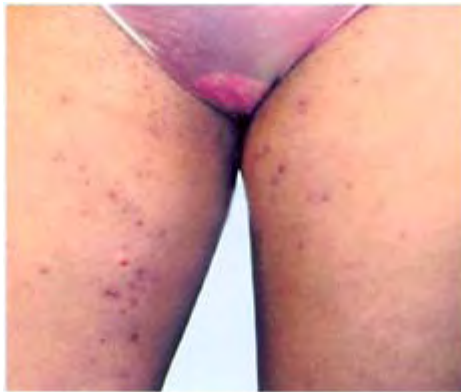**Figure 16.3** Cat scratch disease. DLP ID: *cat scratch disease 124*



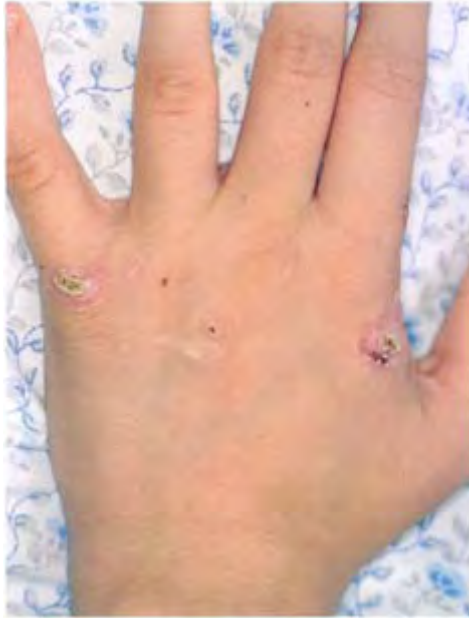**Figure 16.4** Dental sinus. DLP ID: *dental sinus 148*



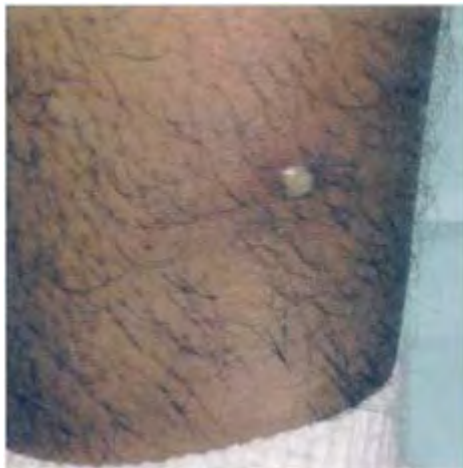**Figure 16.5** Erysipelas, bullous. DLP ID: *erysipelas 56*



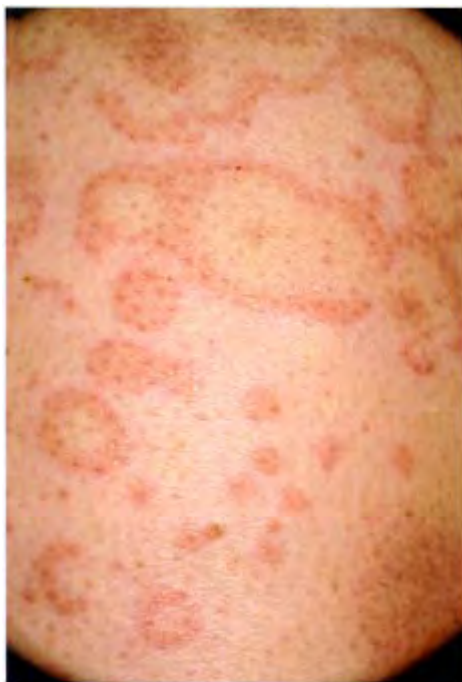**Figure 16.6** Folliculitis due to waxing. DLP ID: *folliculitis 23*



**Figure 16.7** Furuncle. DLP ID: *furuncle 24*

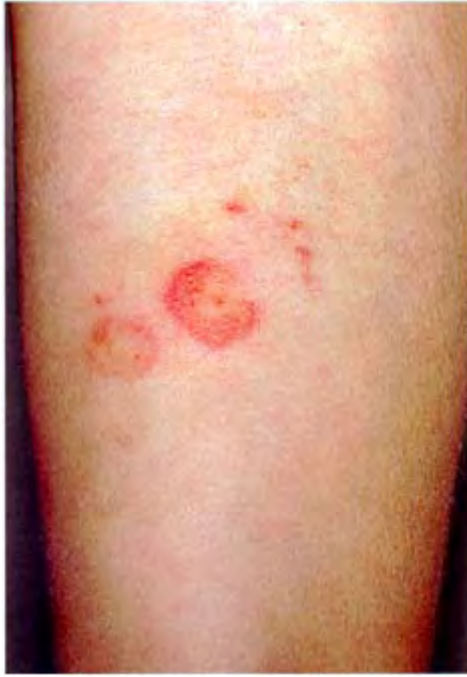

**Figure 16.8** Impetigo. DLP ID: *non-bullous impetigo 19*

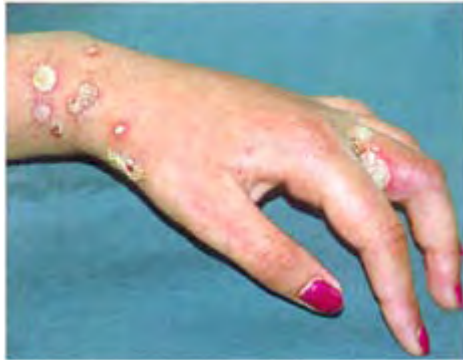

**Figure 16.9** Lyme borreliosis. DLP  
ID: *Lyme disease 255*

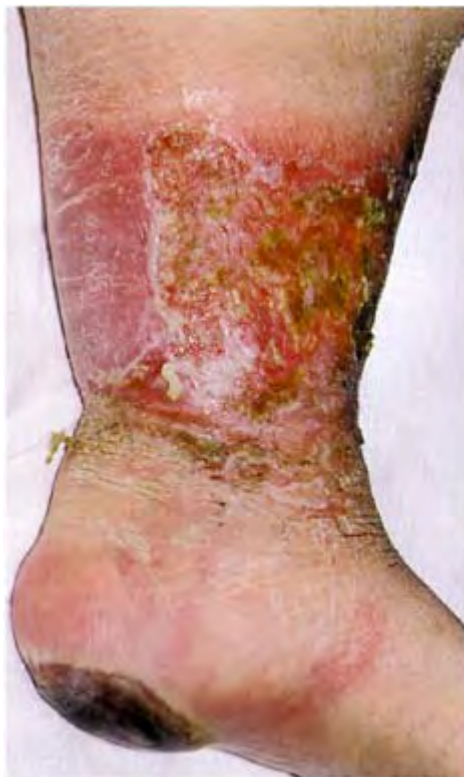



**Figure 16.10** Lyme borreliosis. DLP ID: *Lyme disease 255*

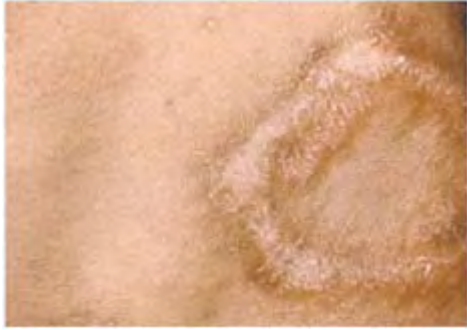

**Figure 16.11** Pyoderma secondary to scabies. DLP ID: *scabies infestation 463*

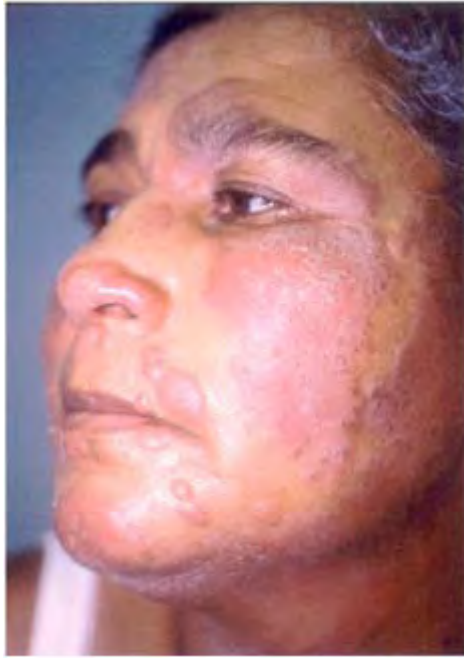

**Figure 16.12** Pyoderma secondary to stasis ulcer. DLP ID: *statis ulcer 2514*

**MYCOBACTERIAL**



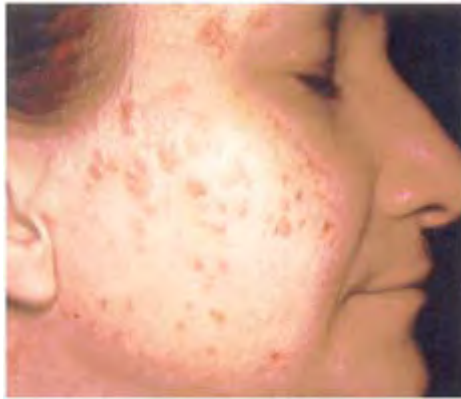**Figure 16.13** Leprosy, borderline.  
DLP ID: *borderline leprosy 182*.  
Courtesy of Dr JHS Pettit, Kuala Lumpur, Malaysia



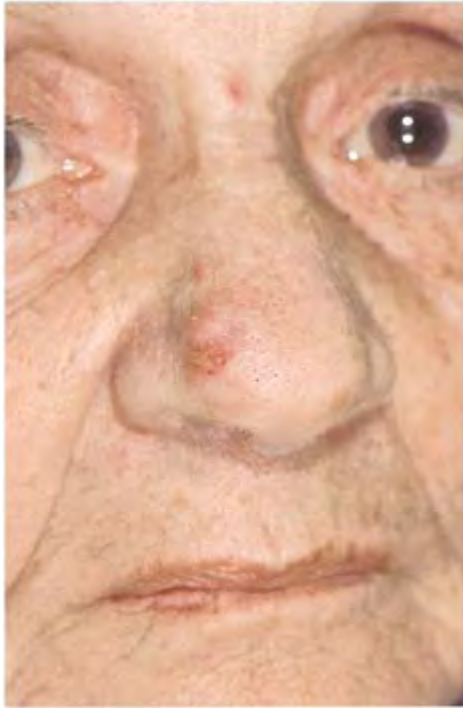**Figure 16.14** Leprosy, lepromatous.  
DLP ID: *borderline lepromatous  
leprosy 183*



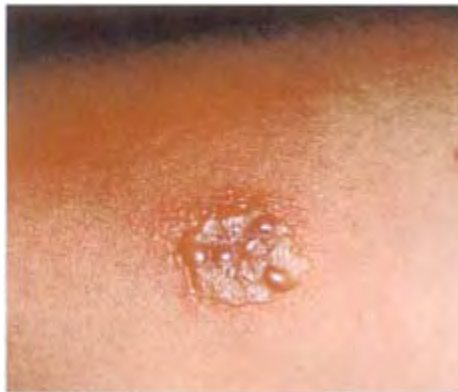**Figure 16.15** Leprosy, tuberculoid.  
DLP ID: *borderline tuberculoid  
leprosy 181*. Courtesy of Dr B Flageul,  
Paris, France



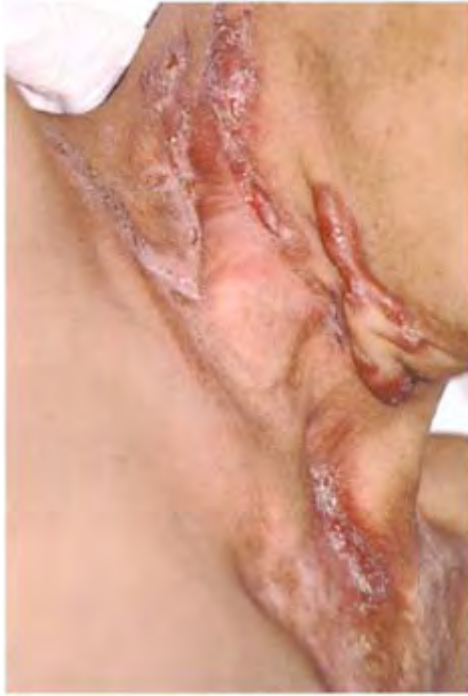**Figure 16.16** Lupus miliaris  
disseminatus faciei. DLP ID:  
*granulomatous rosacea 2312*



**Figure 16.17** Lupus vulgaris. DLP ID: *lupus vulgaris 166*

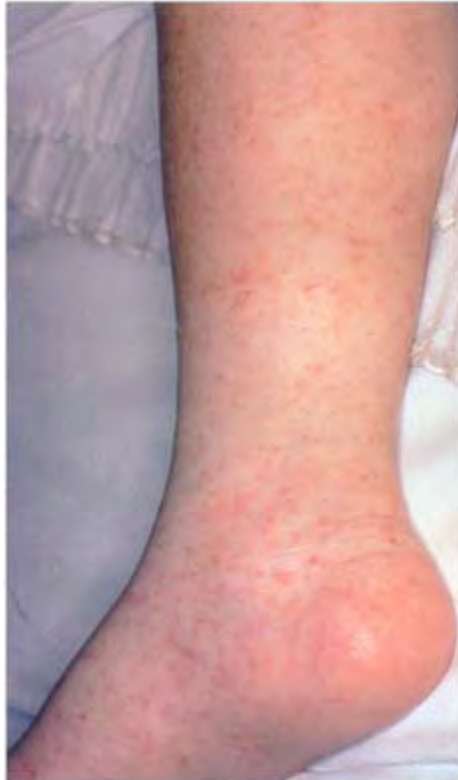

**Figure 16.18** Papulonecrotic tuberculid. DLP ID: *papulonecrotic tuberculid 172*



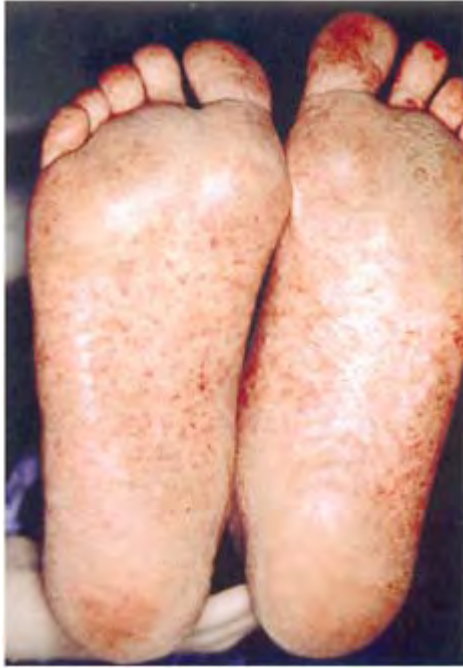**Figure 16.19** Scrofuloderma. DLP ID: *scrofuloderma 167*. Courtesy of Dr KD Pramatarov, Sofia, Bulgaria

**17**  
**Rickettsial diseases**



**Figure 17.1** Rocky Mountain spotted fever. Dermatology Lexicon Project (DLP) preferred term and number: *Rocky Mountain spotted fever 227*

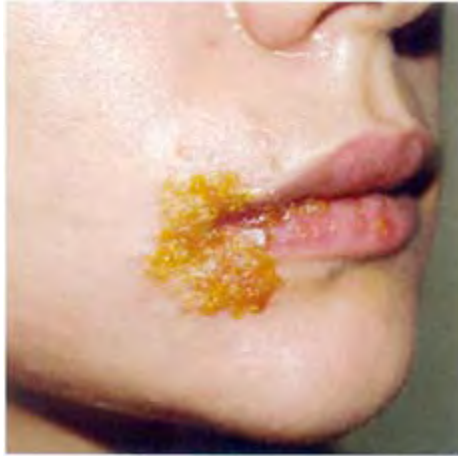



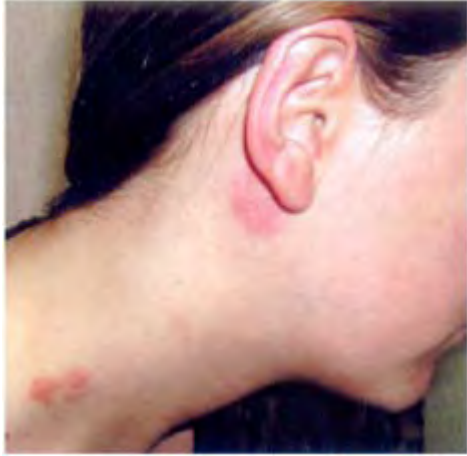**Figure 17.2** Typhus due to *Rickettsia conorii*. DLP ID: *boutonneuse fever*  
236

## 18

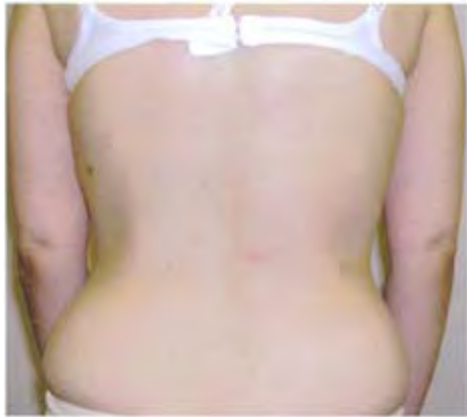### Viral diseases



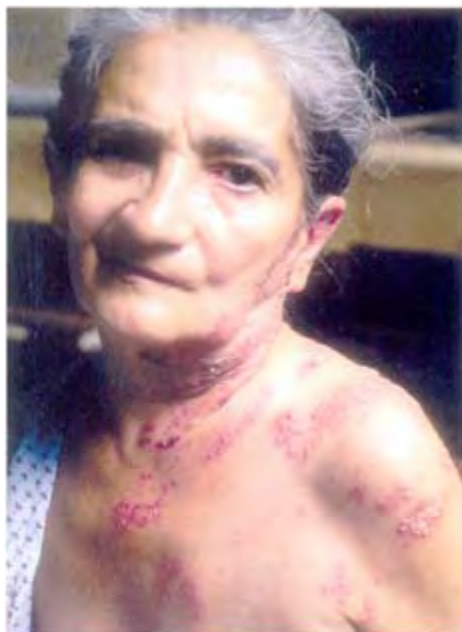**Figure 18.1** Herpes simplex labialis.  
Dermatology Lexicon Project (DLP)  
preferred term and number: *orolabial  
herpes simplex 501*. Courtesy of Dr I  
Botev, Sofia, Bulgaria



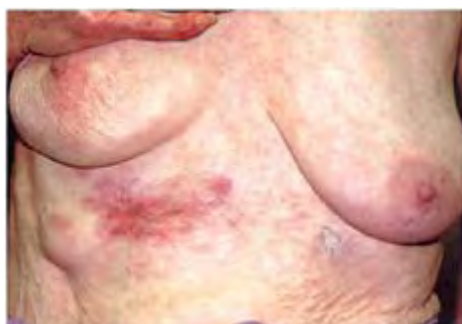**Figure 18.2** Herpes zoster. DLP ID: *herpes zoster virus infection 497*



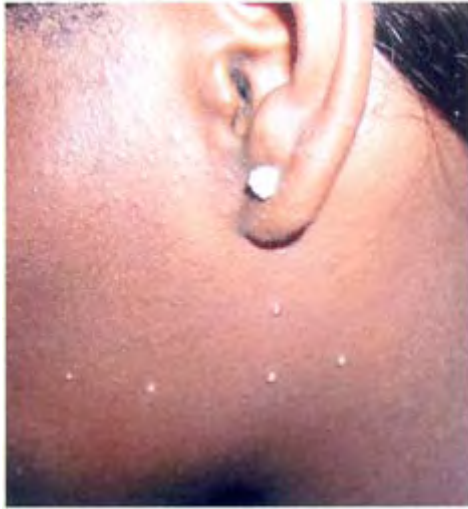**Figure 18.3** Herpes zoster, day one. DLP ID: *herpes zoster virus infection 497*



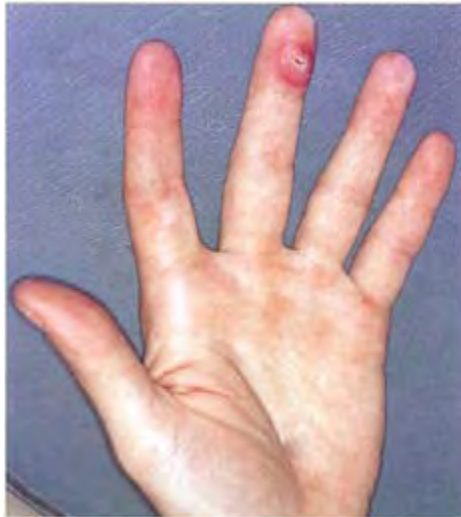**Figure 18.4** Herpes zoster with facial nerve palsy (Ramsay Hunt syndrome). DLP ID: *herpes zoster virus infection 497*



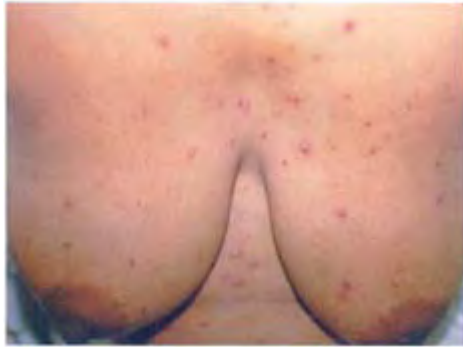**Figure 18.5** Herpes zoster with keloid formation. DLP ID: *herpes zoster virus infection 497 combined with keloid 1264*



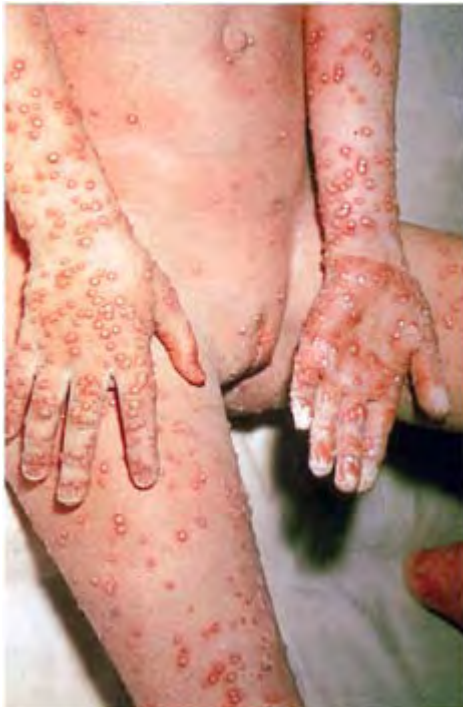**Figure 18.6** Molluscum contagiosum.  
DLP ID: *molluscum contagiosum 575*



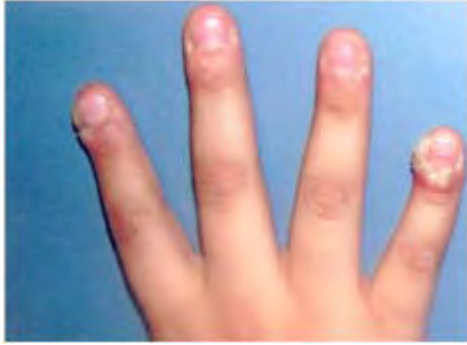**Figure 18.7** Orf (ecthyma contagiosum). DLP ID: *orf 580*



**Figure 18.8** Varicella (chickenpox).  
DLP ID: *varicella virus infection 496*



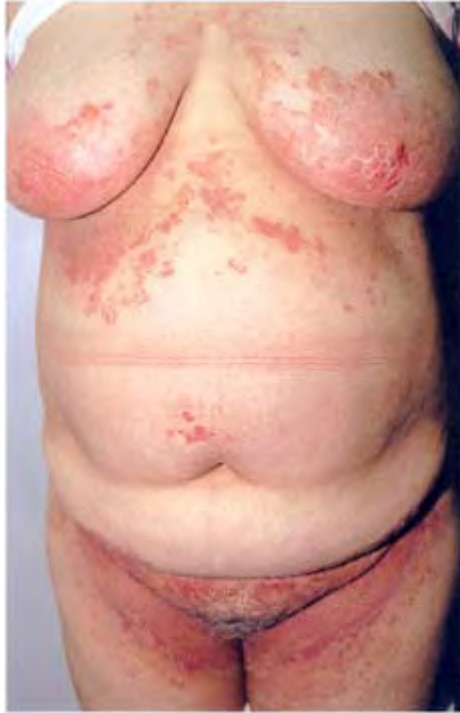**Figure 18.9** Variola (smallpox). DLP  
ID: *smallpox 576*. Courtesy of Dr G  
Stüttgen, Berlin, Germany



**Figure 18.10** Verrucae. DLP ID:  
*verruca vulgaris* 598

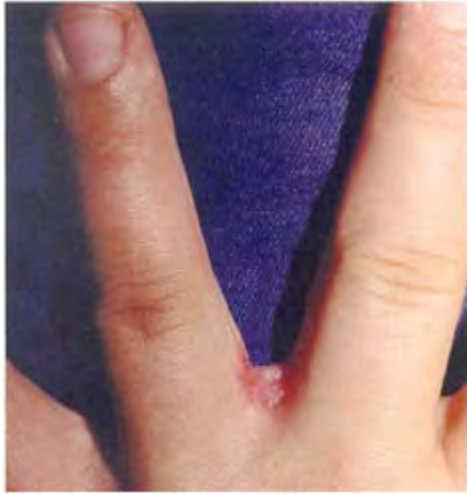**19**  
**Superficial and deep fungal diseases**

**SUPERFICIAL FUNGAL DISEASES**

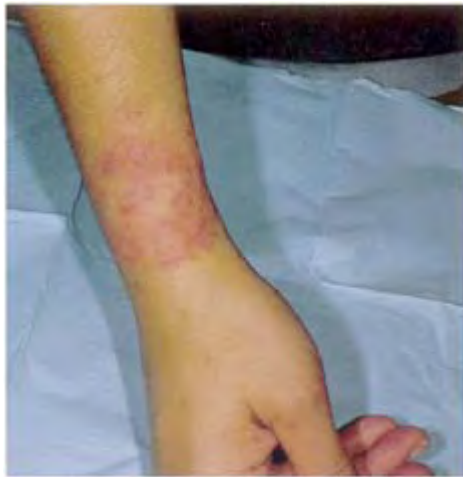

**Figure 19.1** Candidosis. Dermatology Lexicon Project (DLP) preferred term and number: *candidiasis 296*





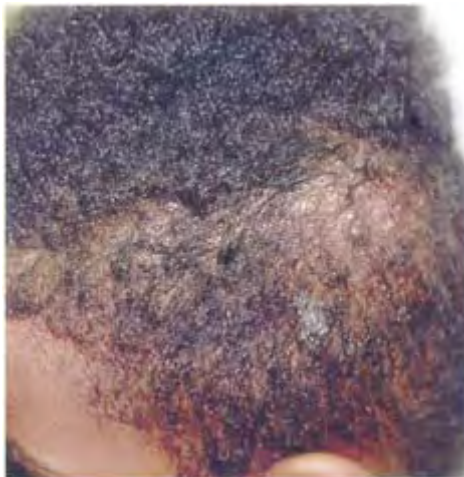**Figure 19.2** Candidosis  
(pseudoblastomycosis interdigitale).  
DLP ID: *erosio interdigitalis*  
*blastomycetica candidiasis 360*



**Figure 19.3** Majocchi's granuloma.  
DLP ID: *Majocchi granuloma 338*



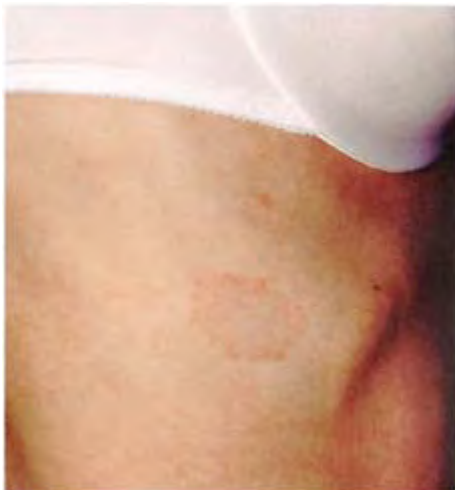**Figure 19.4** Tinea capitis. DLP ID: *tinea capitis 321*



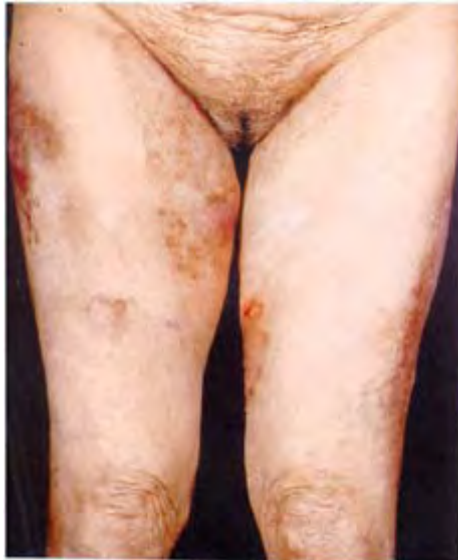**Figure 19.5** Tinea capitis with kerion formation. DLP ID: *tinea capitis 321 combined with kerion 334*



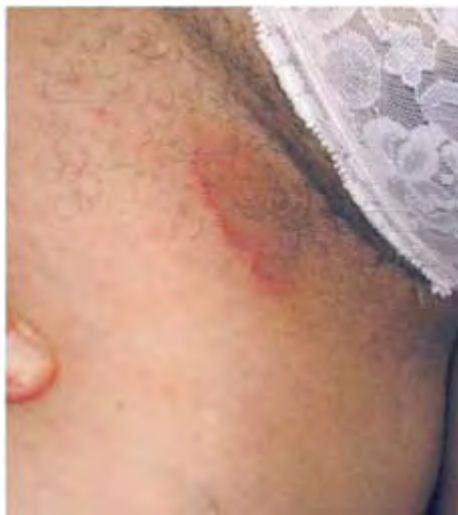**Figure 19.6** Tinea corporis. DLP ID:  
*tinea corporis 324*



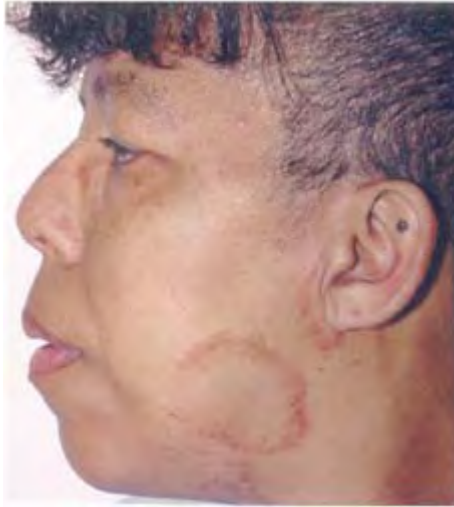**Figure 19.7** Tinea corporis. DLP ID:  
*tinea corporis 324*



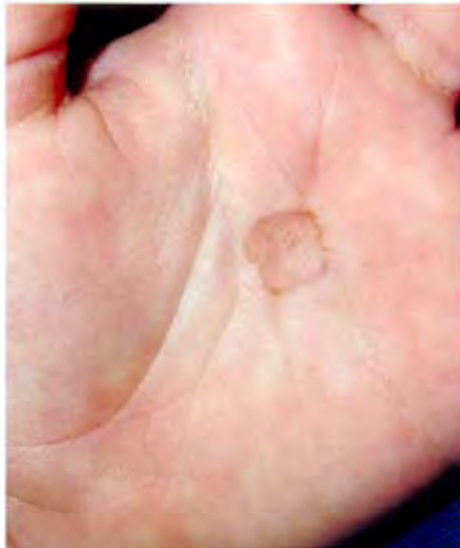**Figure 19.8** Tinea corporis augmented by topical steroids (tinea incognita).  
DLP ID: *tinea incognito* 326



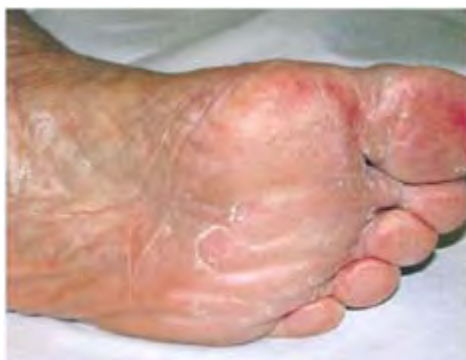**Figure 19.9** Tinea cruris. DLP ID: *tinea cruris* 327. Courtesy of Dr N Fernandes, Rio de Janeiro, Brazil



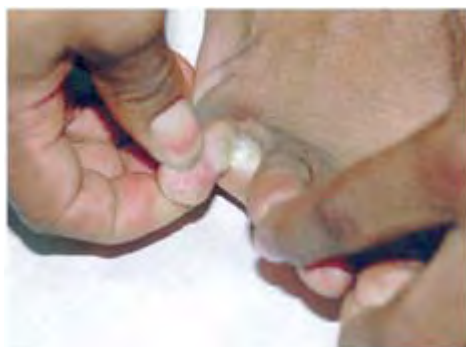**Figure 19.10** Tinea faciei. DLP ID: *tinea faciale 325*



**Figure 19.11** Tinea nigra. DLP ID: *tinea nigra 342*. Courtesy of Dr N Fernandes, Rio de Janeiro, Brazil



**Figure 19.12** Tinea pedis. DLP ID:  
*tinea pedis 328*

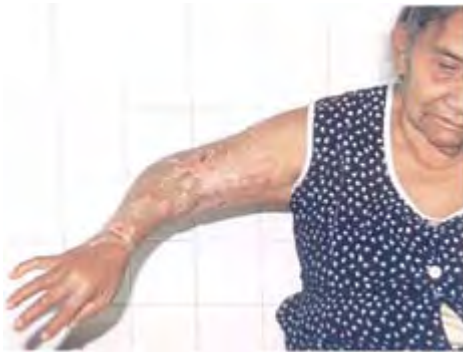

**Figure 19.13** Tinea pedis. DLP ID:  
*tinea pedis 328*

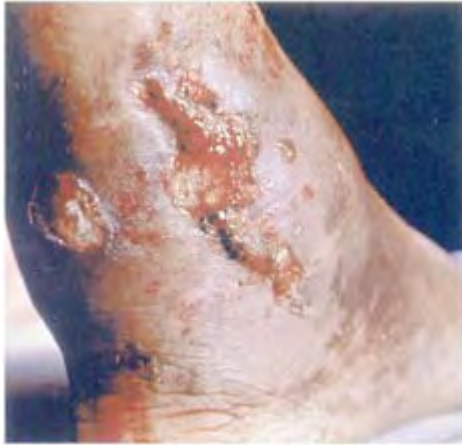

**Figure 19.14** Tinea versicolor. DLP  
ID: *tinea versicolor* 343

### SUBCUTANEOUS AND DEEP FUNGAL DISEASES

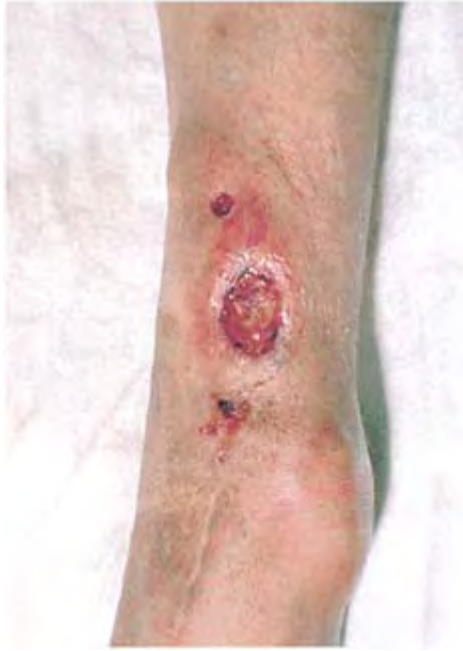

**Figure 19.15** Chromoblastomycosis.  
DLP ID: *chromoblastomycosis* 299

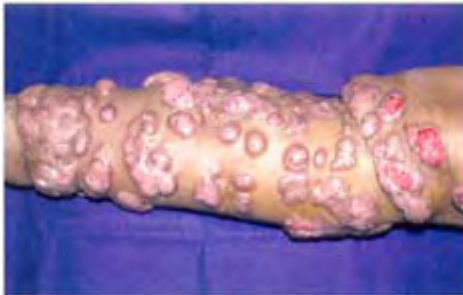

**Figure 19.16** Coccidiomycosis. DLP ID: *coccidioidomycosis 310*. Courtesy of Dr JHS Pettit, Kuala Lumpur, Malaysia

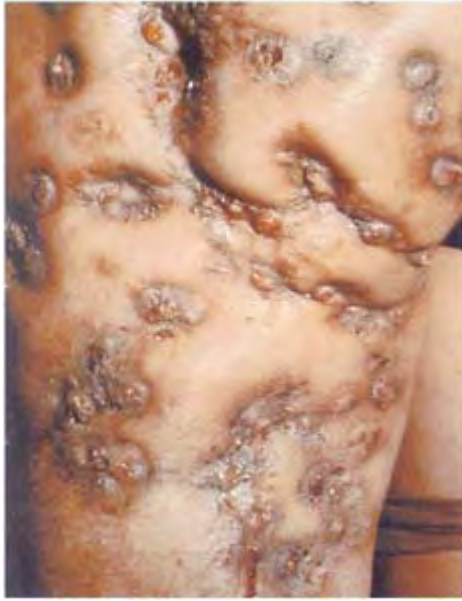



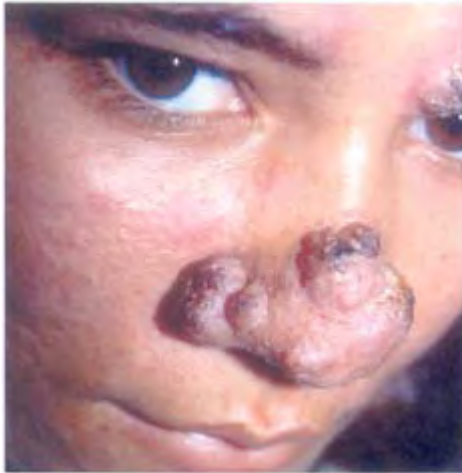**Figure 19.17** Cryptococcosis. DLP ID: *cryptococcosis 309*. Courtesy of Dr S Sampaio, Sao Paulo, Brazil



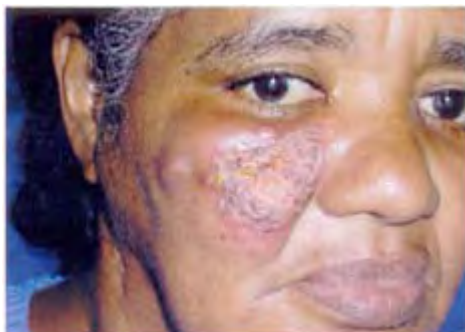**Figure 19.18** Lobomycosis. DLP ID: *lobomycosis 302*. Courtesy of Dr A de Brito, Rio de Janeiro, Brazil



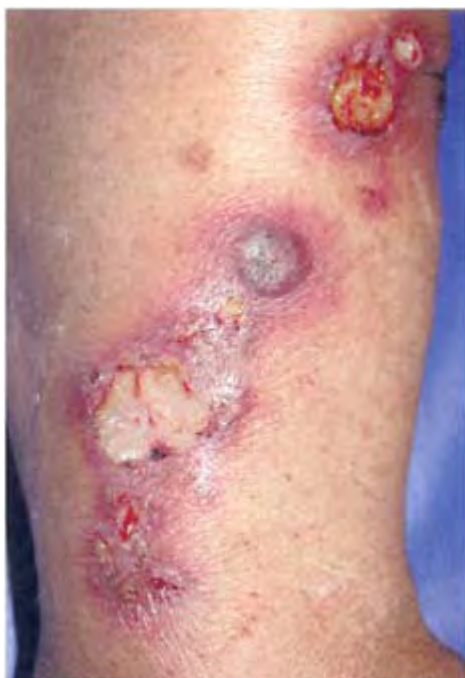**Figure 19.19** Mycetoma. DLP ID: *mycetoma 388*



**Figure 19.20** Paracoccidioidomycosis (South American blastomycosis). DLP ID: *paracoccidioidomycosis 308*

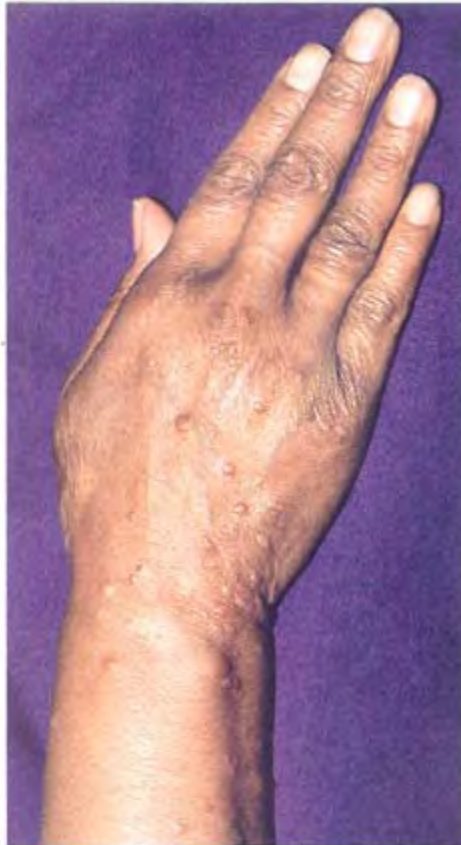

**Figure 19.21** Sporotrichosis. DLP ID: *sporotrichosis 298*. Courtesy of Drs N Fernandes and G Munhoz-da-Fontoura, Rio de Janeiro, Brazil

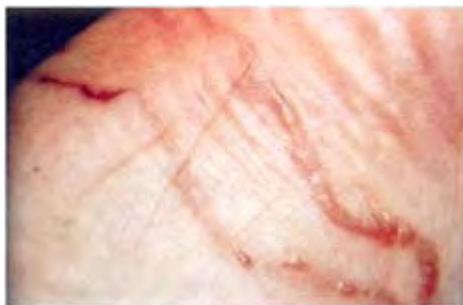

**Figure 19.22** Sporotrichosis in a woman with multiple myeloma. DLP ID: *sporotrichosis 298*

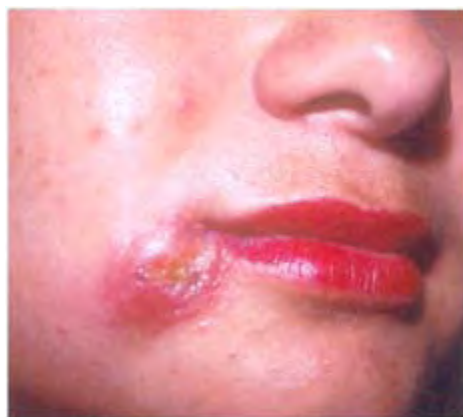**20**  
**Parasitic diseases**




**Figure 20.1** Insect bite reaction.  
Dermatology Lexicon Project (DLP)  
preferred term and number: *arthropod*  
*bite 3596*



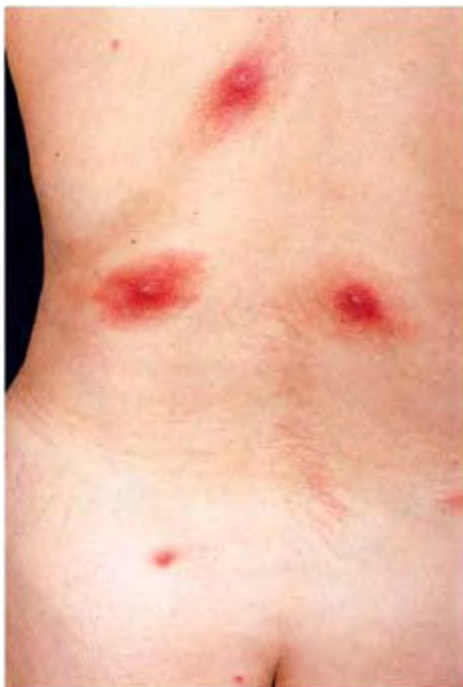**Figure 20.2** Larva migrans. DLP ID: *cutaneous larva migrans 417*.  
Courtesy of Dr W Höffler, Tübingen,  
Germany



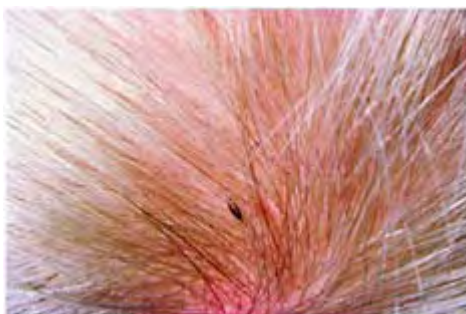**Figure 20.3** Leishmaniasis, cutaneous  
American. DLP ID: *New World  
leishmaniasis 407*



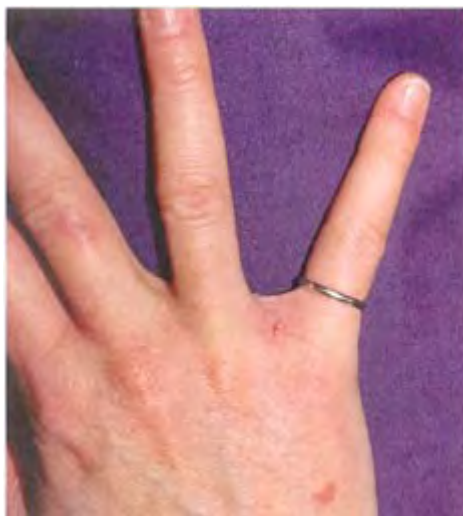**Figure 20.4** Leishmaniasis, cutaneous American. DLP ID: *New World leishmaniasis 407*



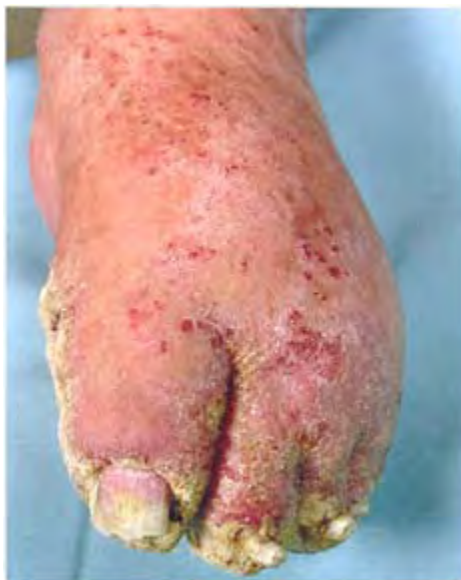**Figure 20.5** Myiasis. DLP ID: *myiasis 464*



**Figure 20.6** Pediculosis capitis. DLP ID: *pediculosis capitis 465*

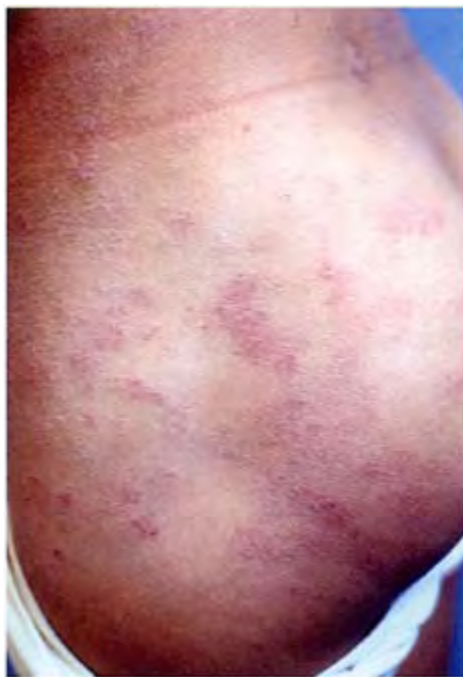

**Figure 20.7** Scabies. DLP ID: *scabies infestation 463*

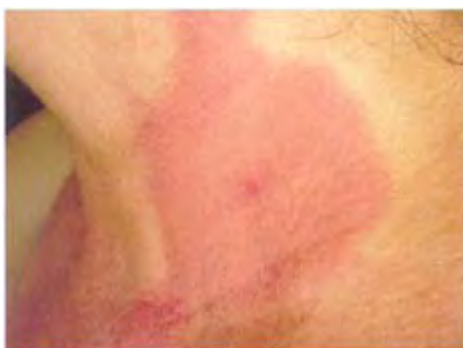

**Figure 20.8** Scabies, crusted. DLP ID:  
*crusted scabies 469*

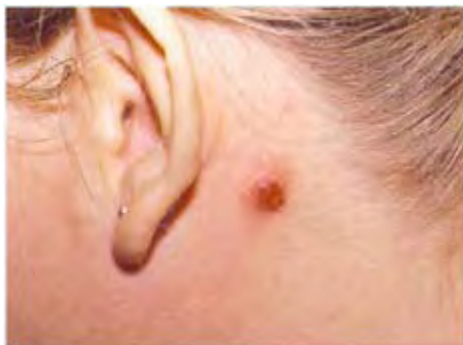



**Figure 20.9** Scabies in an elderly patient. DLP ID: *scabies infestation 463*



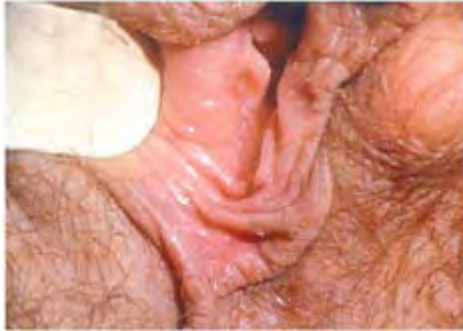**Figure 20.10** Spider bite, type unknown. DLP ID: *spider bite 3642*



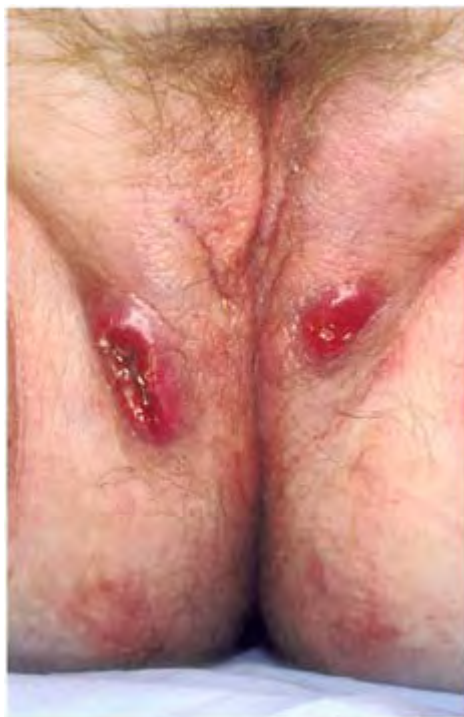**Figure 20.11** Tick bite. DLP ID: *tick bite 3654*

## Sexually transmitted disease and AIDS

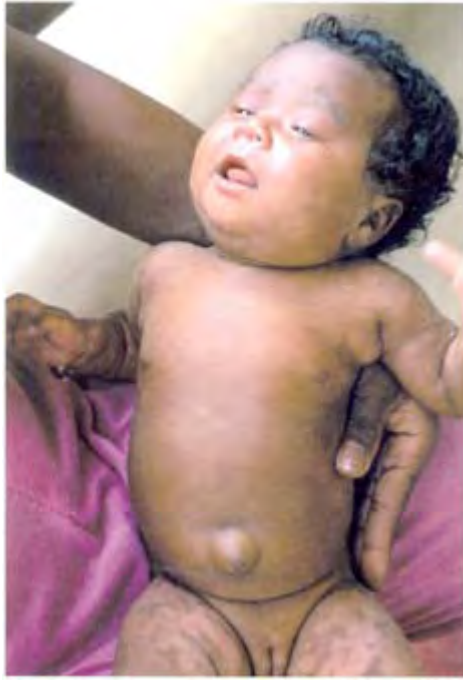### SEXUALLY TRANSMITTED DISEASES



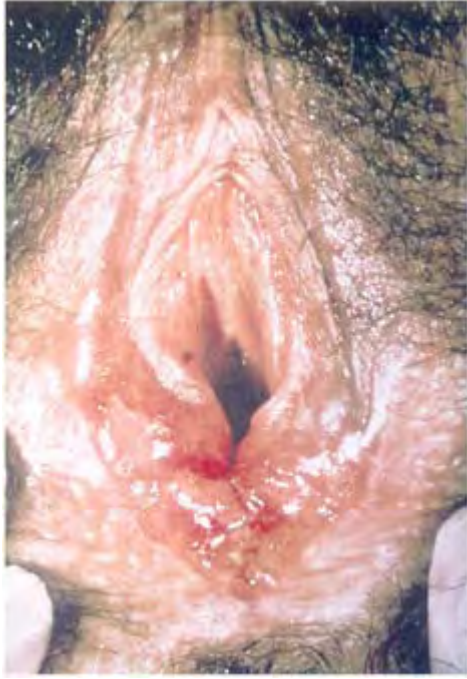**Figure 21.1** Chancroid. Dermatology Lexicon Project (DLP) preferred term and number: *chancroid 89*. Courtesy of Dr RCV Robinson, Baltimore, MD



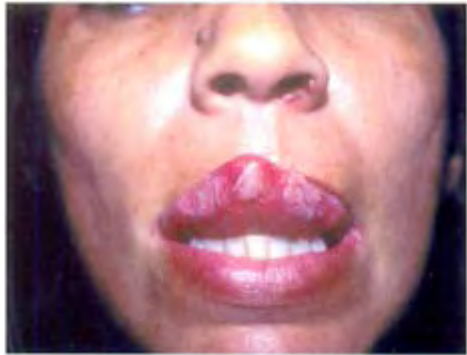**Figure 21.2** Granuloma inguinale.  
DLP ID: *granuloma inguinale* 88.  
Courtesy of Dr B Fisher, Tel Aviv,  
Israel



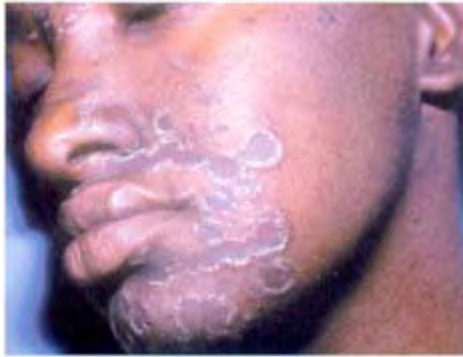**Figure 21.3** Syphilis, congenital. DLP  
ID: *congenital syphilis 271*



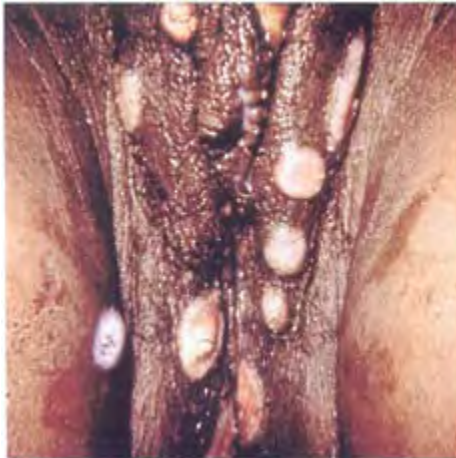**Figure 21.4** Syphilis, primary. DLP  
ID: *primary syphilis 268*



**Figure 21.5** Syphilis, secondary. DLP  
ID: *secondary syphilis 269*



**Figure 21.6** Syphilis, secondary. DLP ID: *secondary syphilis 269*

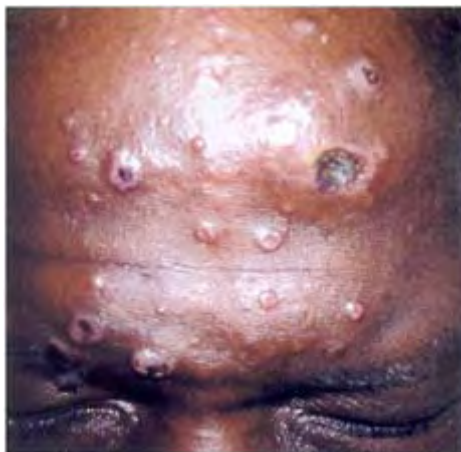

**Figure 21.7** Syphilis, secondary—  
condylomata lata. DLP ID: *condyloma  
lata of secondary syphilis 273*



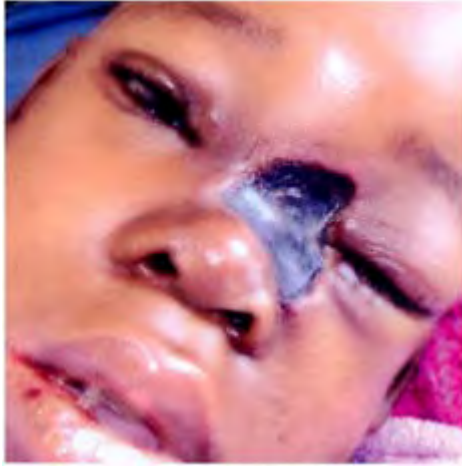**Figure 21.8** Syphilis tertiary. DLP ID: *tertiary syphilis 270*

#### AIDS

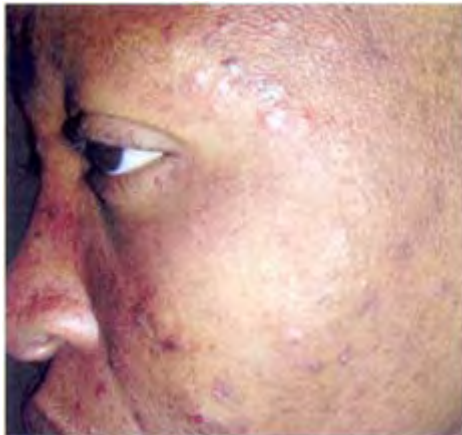

**Figure 21.9** Cryptococcosis in an AIDS patient. DLP ID: *cryptococcosis 309*. Courtesy of Drs NC Dlova and A Mosam, Durban, South Africa

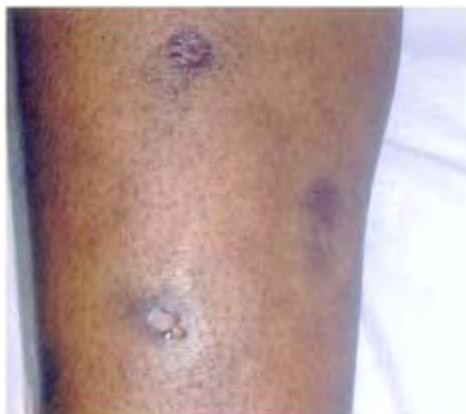



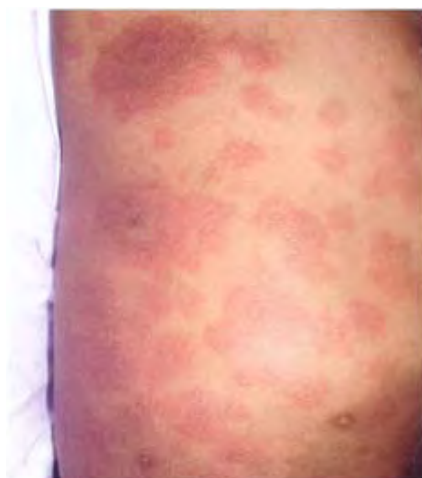**Figure 21.10** Cytomegalovirus infection (CMV) in an AIDS patient. DLP ID: *cytomegalovirus infection* 499. Courtesy of Drs NC Dlova and A Mosam, Durban, South Africa



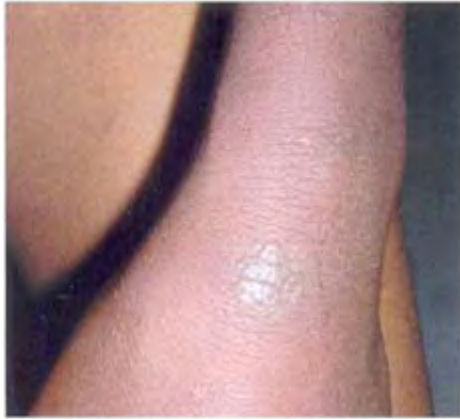**Figure 21.11** Eosinophilic folliculitis in an AIDS patient. DLP ID: *eosinophilic folliculitis* 2323. Courtesy of Drs NC Dlova and A Mosam, Durban, South Africa



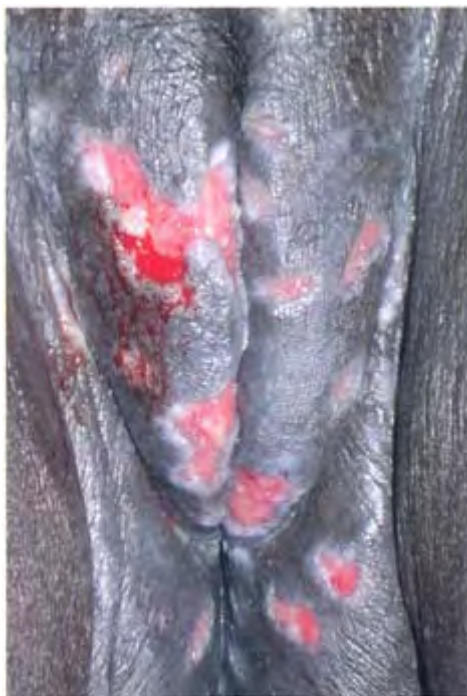**Figure 21.12** Erythema induratum associated with tuberculosis in an AIDS patient. DLP ID: *erythema induratum 2356*. Courtesy of Drs NC Dlova and A Mosam, Durban, South Africa



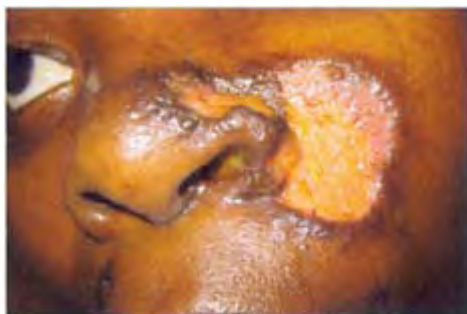**Figure 21.13** Erythema multiforme due to trimethoprim-sulfamethoxazole in an AIDS patient. DLP ID: *erythema multiforme major 1876*. Courtesy of Drs NC Dlova and A Mosam, Durban, South Africa



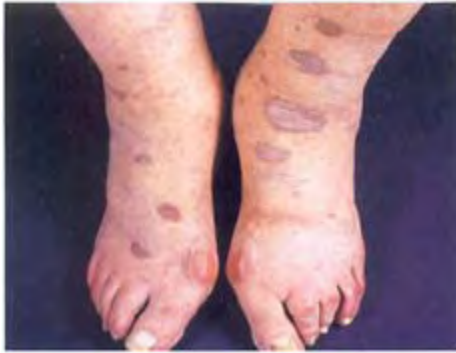**Figure 20.14** Fixed drug eruption (DE) due to trimethoprim-sulfamethoxazole in an AIDS patient. DLP ID: *fixed drug eruption 1887*. Courtesy of Drs NC Dlova and A Mosam, Durban, South Africa



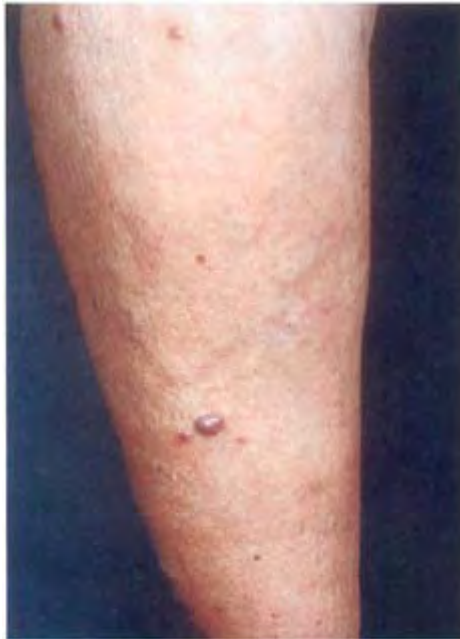**Figure 21.15** Herpes proies genitalis in an AIDS patient. DLP ID: *genital herpes simplex 502*. Courtesy of Drs NC Dlova and A Mosam, Durban, South Africa



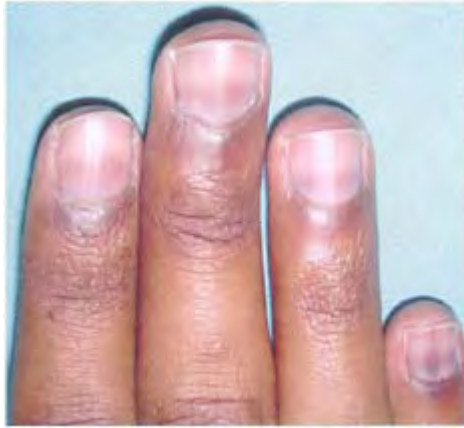**Figure 21.16** Histoplasmosis in an AIDS patient. DLP ID: *histoplasmosis 306*. Courtesy of Drs NC Dlova and A Mosam, Durban, South Africa



**Figure 21.17** Kaposi's sarcoma in an AIDS patient. DLP ID: *immunosuppression-related Kaposi sarcoma 1457*



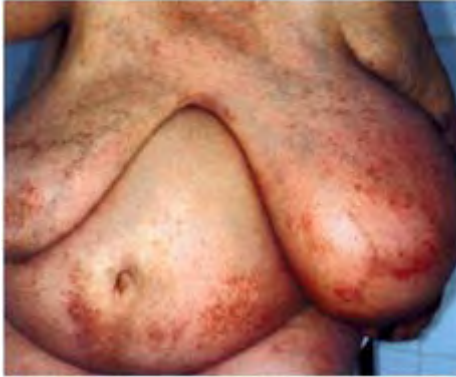**Figure 21.18** Kaposi's sarcoma in an AIDS patient. DLP ID: *immunosuppression-related Kaposi sarcoma 1457*



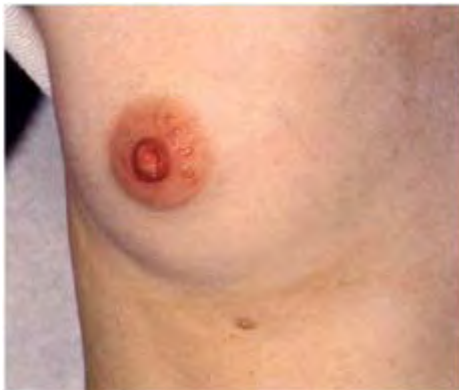**Figure 21.19** Melanonychia following zidovudine (AZT) therapy in an AIDS patient. DLP ID: *melanonychia striata* 1082. Courtesy of Drs NC Dlova and A Mosam, Durban, South Africa

# Topographic dermatology

**Diseases of the breast**

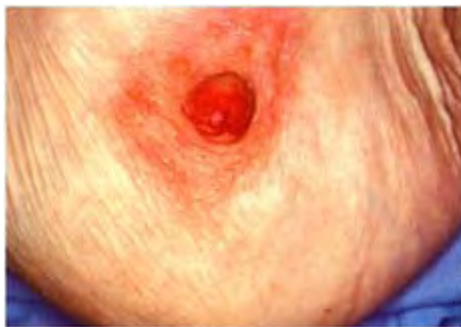

**Figure 22.1** Abscess. Dermatology Lexicon Project (DLP) preferred term and number: *abscess 34*

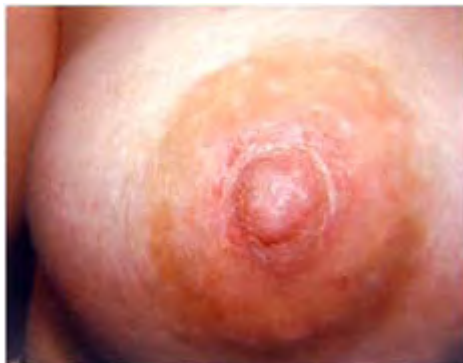

**Figure 22.2** Accessory (supernumerary) nipple. DLP ID: *accessory nipple 4314*

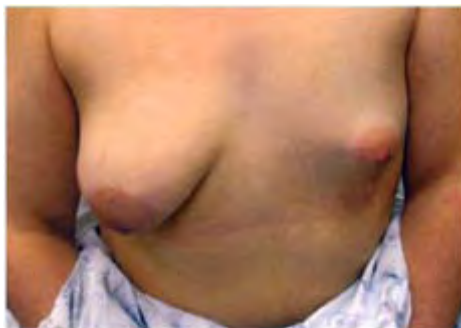



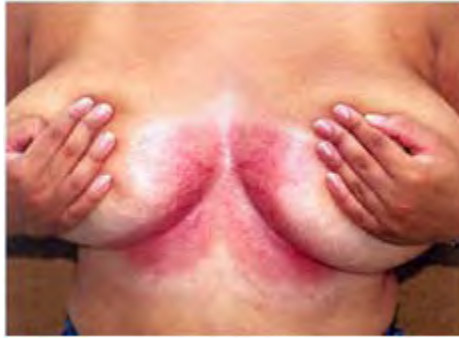**Figure 22.3** Adenomatosis, erosive.  
DLP ID: *nipple erosive adenomatosis*  
924



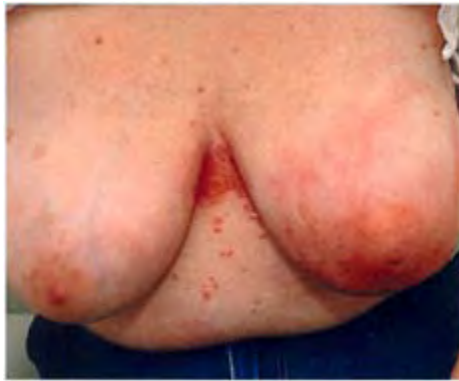**Figure 22.4** Atopic dermatitis. DLP  
ID: *atopic dermatitis* 2100



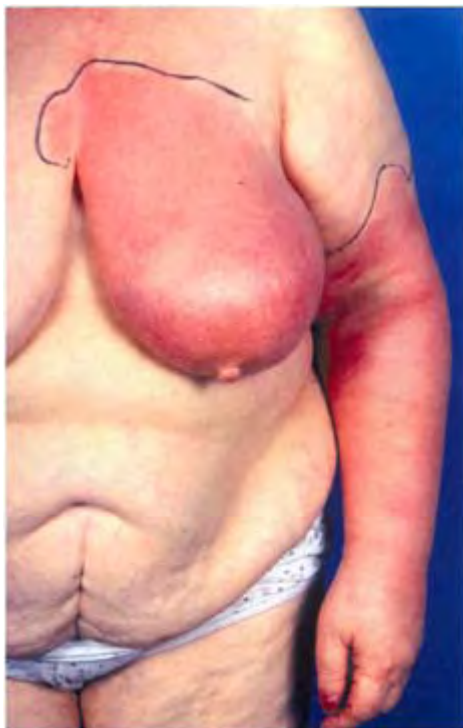**Figure 22.5** Breast, hypoplastic. DLP  
ID: *hypoplastic breast* 6677



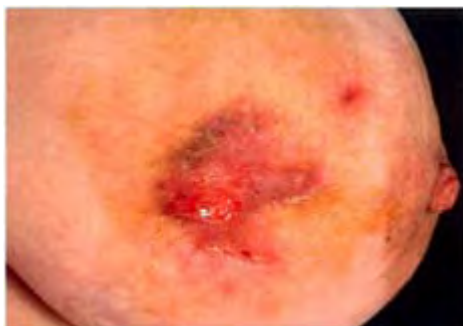**Figure 22.6** Candidosis. DLP ID:  
*candidiasis 296*



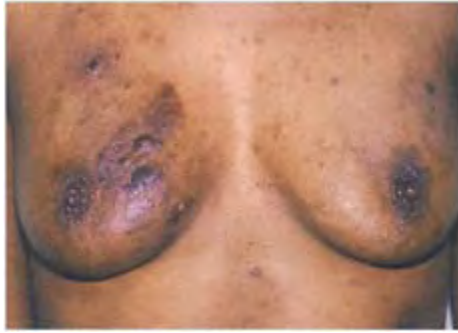**Figure 22.7** Candidosis. DLP ID:  
*candidiasis 296*



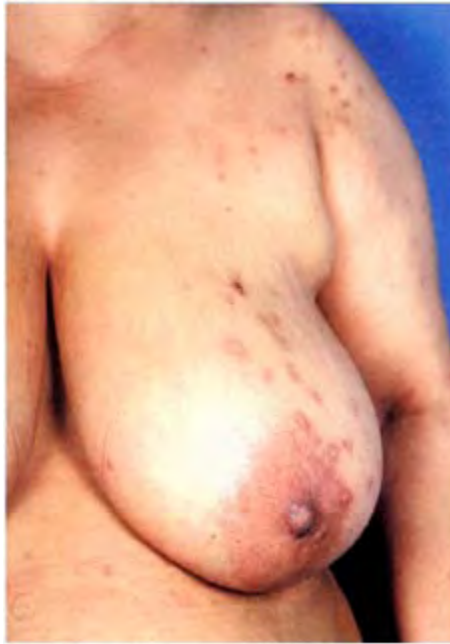**Figure 22.8** Erysipelas, post-lumpectomy 13 years prior. DLP ID: *erysipelas 56*



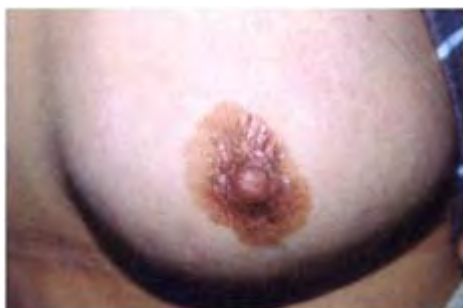**Figure 22.9** Factitial dermatitis. DLP ID: *dermatitis artefacta 617*



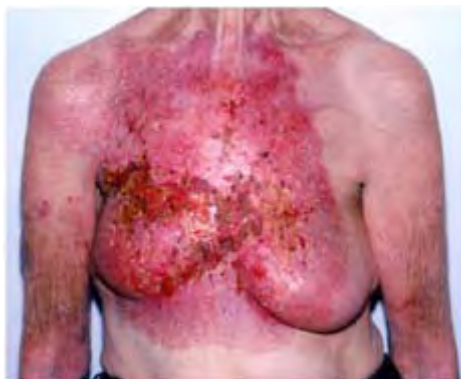**Figure 22.10** Keloids. DLP ID: *keloid 1264*



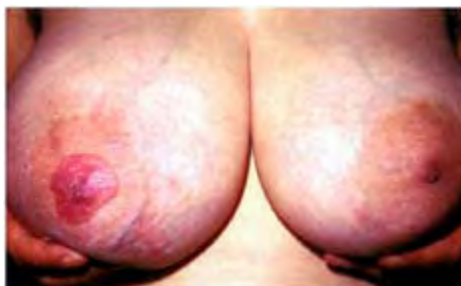**Figure 22.11** Neurotic excoriations. DLP ID: *dermatitis artefacta 617*



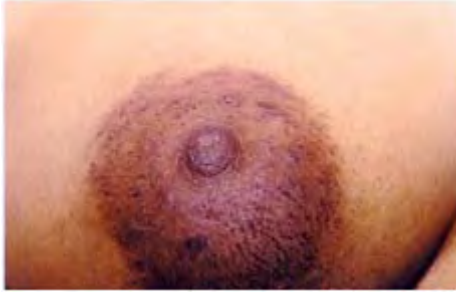**Figure 22.12** Paget's disease. DLP ID:  
*Paget disease of breast 4549*



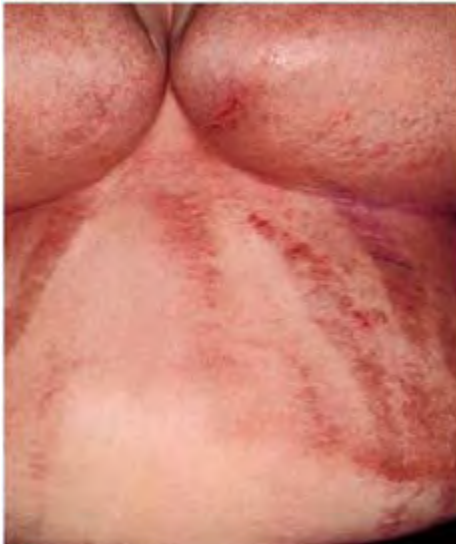**Figure 22.13** Paget's disease. DLP ID:  
*Paget disease of breast 4549*



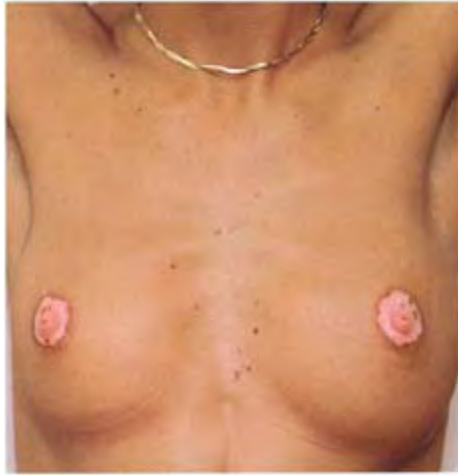**Figure 22.14** Paget's disease disc.  
DLP ID: *Paget disease of breast 4549*



**Figure 22.15** Seborrheic keratosis.  
DLP ID: *seborrheic keratosis 753*

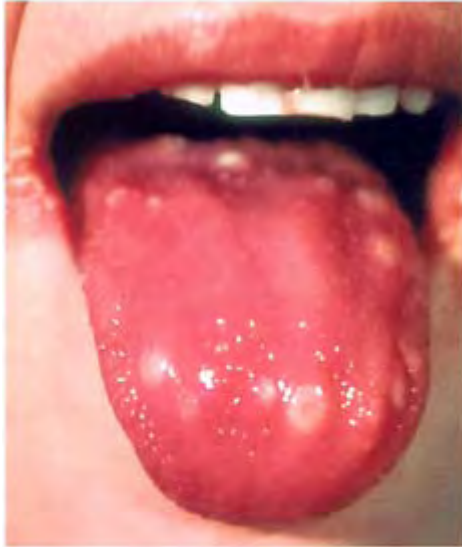

**Figure 22.16** Striae due to chronic use  
of a potent steroid/antifungal cream.  
DLP ID: *striae due to topical  
corticosteroid 4212*

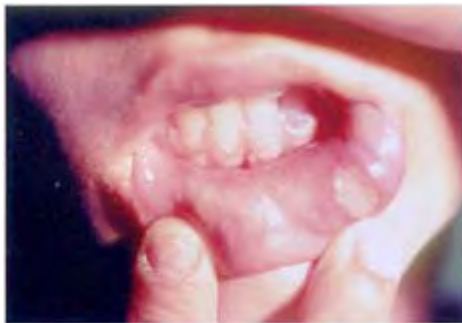

**Figure 22.17** Vitiligo. DLP ID: *vitiligo 1839*

## 23 Oral lesions

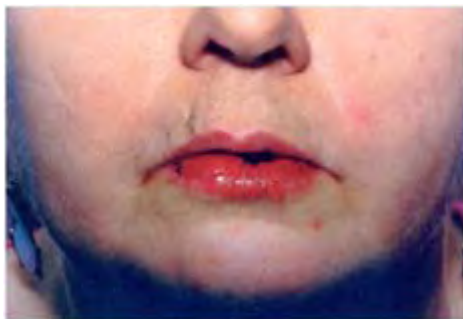

**Figure 23.1** Aphthous stomatitis, etiology undetermined. Dermatology Lexicon Project (DLP) preferred term and number: *aphthous stomatitis 2331*

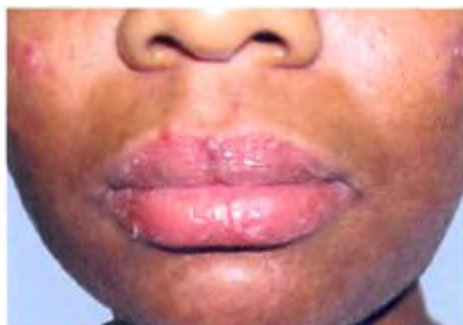

**Figure 23.2** Behçet's disease. DLP ID: *Behçet's disease 2166*

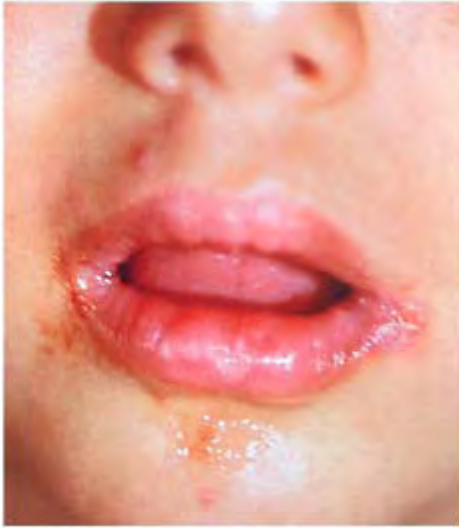



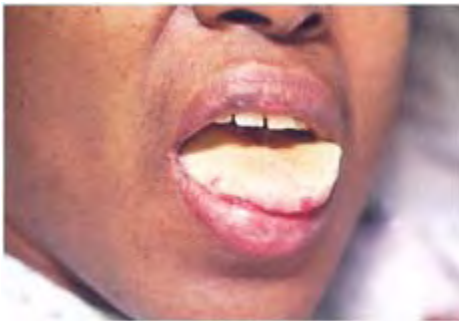**Figure 23.3** Cheilitis, actinic. DLP ID: *actinic cheilitis 776*



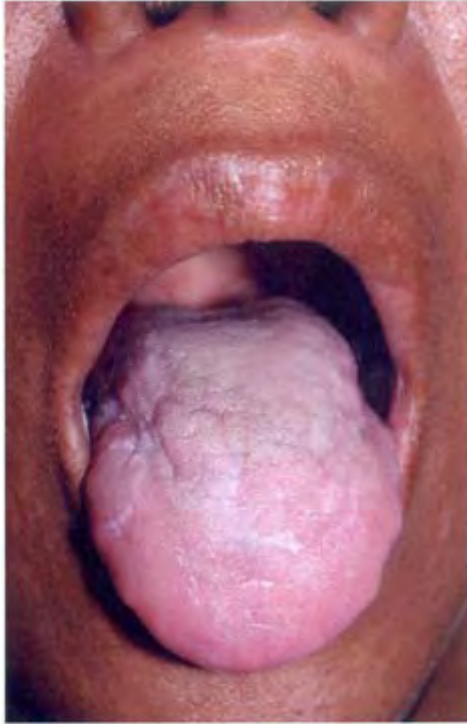**Figure 23.4** Cheilitis due to oral isotretinoin therapy. DLP ID: *cheilitis, drug induced 4227*



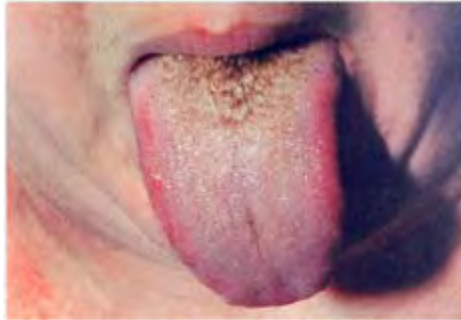**Figure 23.5** Hand, foot, and mouth disease. DLP ID: *hand-foot-mouth disease 565*



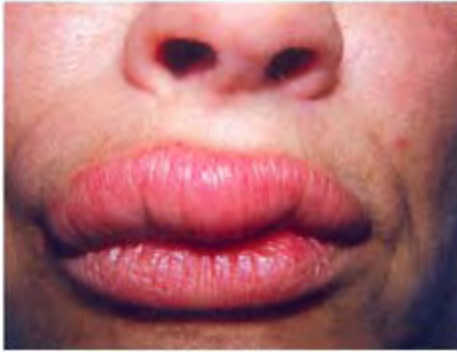**Figure 23.6** Herpes simplex labialis, primary infection. DLP ID: *orolabial herpes simplex 501*



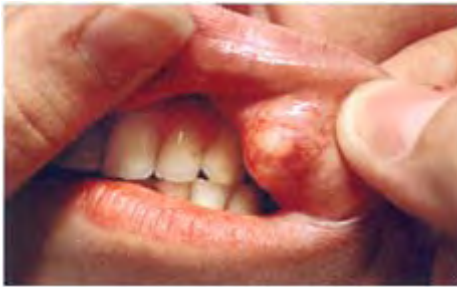**Figure 23.7** Lichen planus. DLP ID:  
*lichen planus 4843*



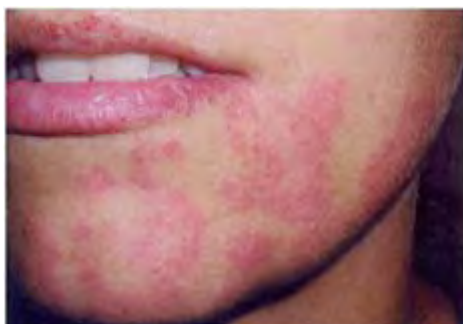**Figure 23.8** Lingua nigra. DLP ID:  
*black tongue 4235*



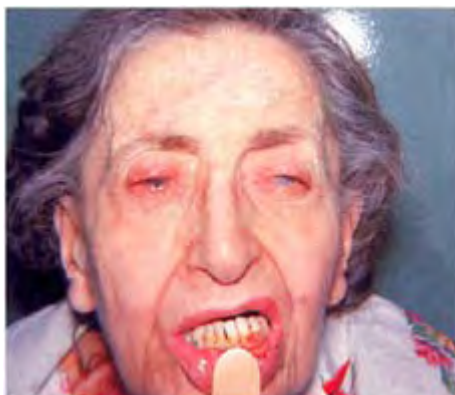**Figure 23.9** Melkersson-Rosenthal syndrome. DLP ID: *Melkersson-Rosenthal syndrome 705*



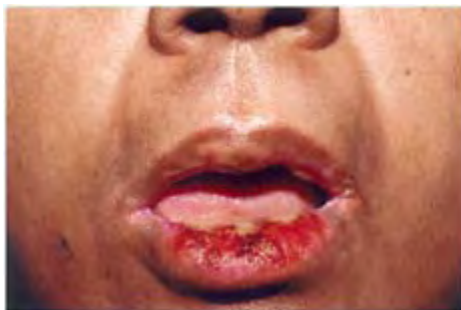**Figure 23.10** Mucocele. DLP ID: *mucocele 851*



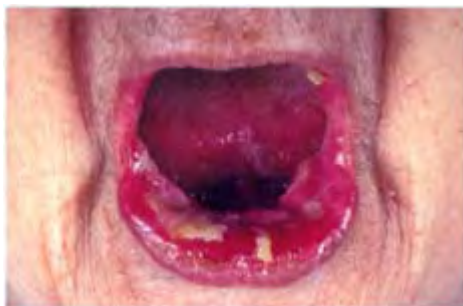**Figure 23.11** Osier-Weber-Rendu syndrome. DLP ID: *hereditary hemorrhagic telangiectasia 1411*. Courtesy of Drs C Sodre and G Munhoz-da-Fontoura; Rio de Janeiro, Brazil



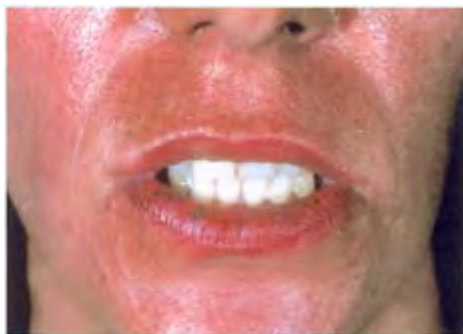**Figure 23.12** Pemphigoid, cicatricial. DLP ID: *cicatricial pemphigoid 1761*



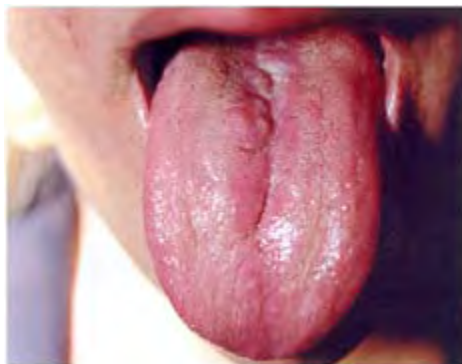**Figure 23.13** Pemphigus foliaceus.  
DLP ID: *pemphigus foliaceus* 1750



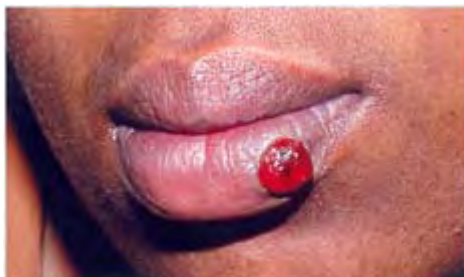**Figure 23.14** Pemphigus vulgaris.  
DLP ID: *pemphigus vulgaris* 1748



**Figure 23.15** Peutz-Jeghers syndrome.  
DLP ID: *Peutz-Jeghers syndrome* 3245

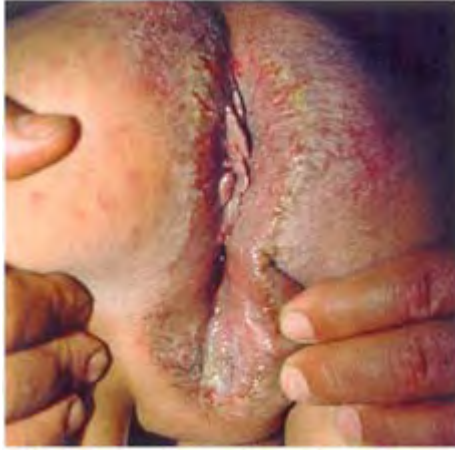

**Figure 23.16** Pseudoepitheliomatous hyperplasia. DLP ID: *pseudoepitheliomatous hyperplasia 738*. Courtesy of Dr O Oumeish, Amman, Jordan

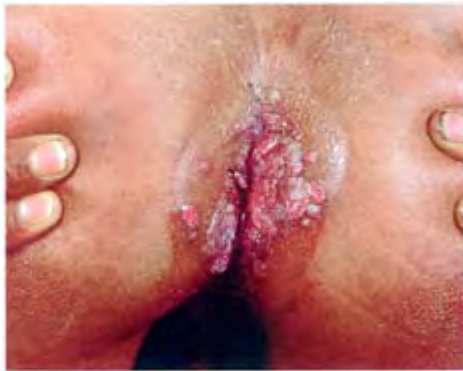

**Figure 23.17** Pyogenic granuloma. DLP ID: *pyogenic granuloma 2823*

## Perineal and perianal diseases



**Figure 24.1** Candidosis, chronic mucocutaneous and condyloma acuminata. Dermatology Lexicon Project (DLP) preferred term and number: *chronic mucocutaneous candidiasis 364*

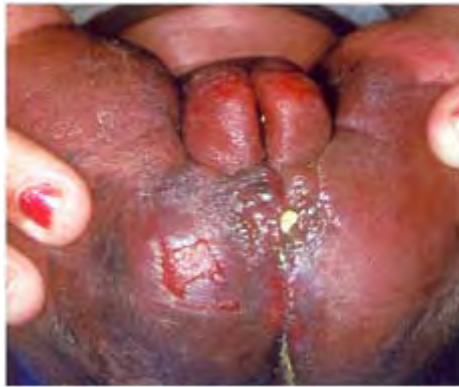

**Figure 24.2** Condyloma acuminata. DLP ID: *condyloma acuminata 603*

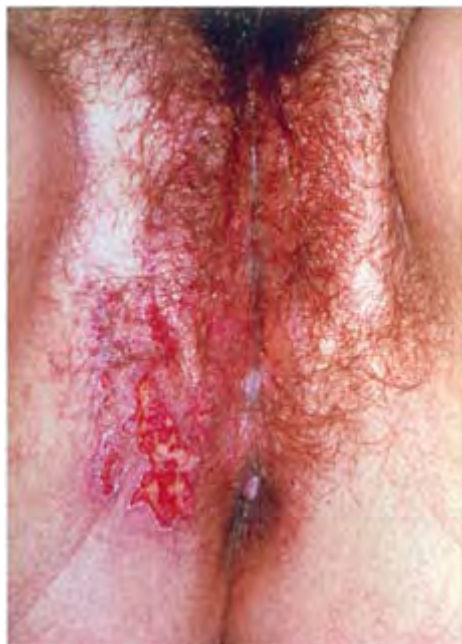



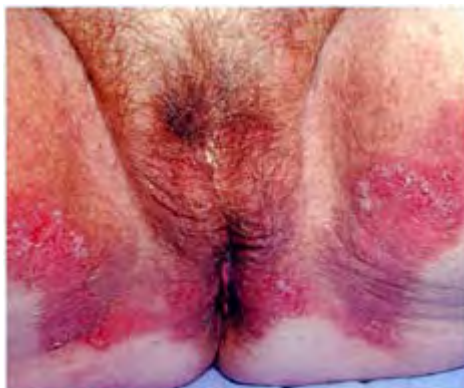**Figure 24.3** Condyloma acuminata.  
DLP ID: *condyloma acuminata 603*



**Figure 24.4** Nevus, congenital. DLP  
ID: *congenital nevus 1020*

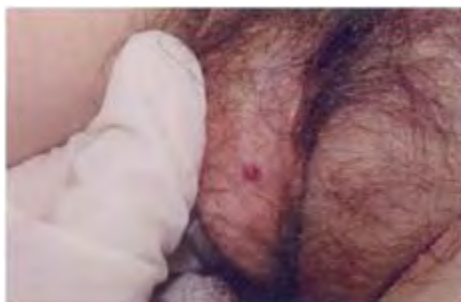

**Figure 24.5** Paget's disease, extramammary. DLP ID: *Paget disease 966*

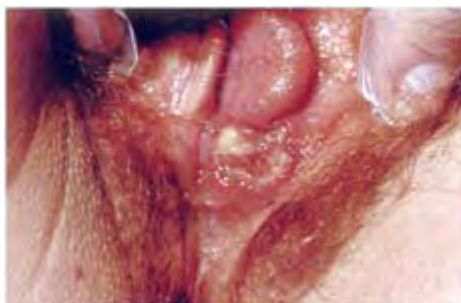

**Figure 24.6** Pemphigus, benign familial chronic (Hailey-Hailey disease). DLP ID: *Hailey-Hailey disease 3503*

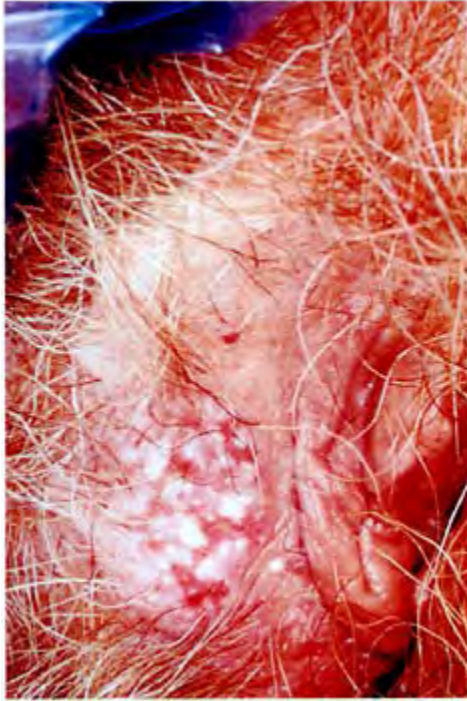
## 25 Diseases of the vulva



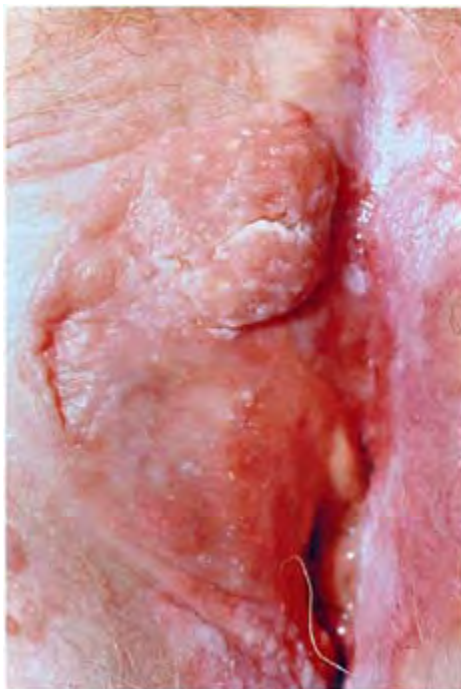**Figure 25.1** Angioma. Dermatology Lexicon Project (DLP) preferred term and number: *hemangioma, unclassified 5263*



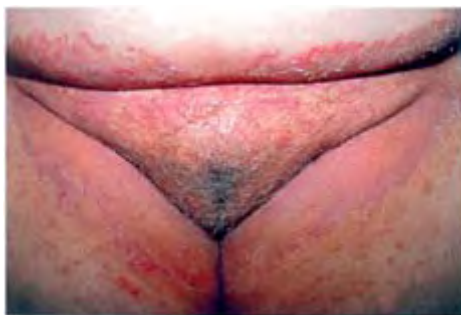**Figure 25.3** Behçet's disease. DLP ID: *Behçet's disease 2166*



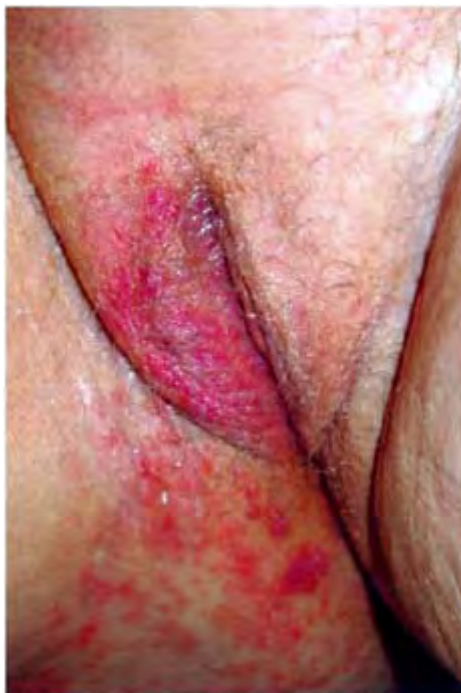**Figure 25.2** Basal cell carcinoma.  
DLP ID: *basal cell carcinoma 797*



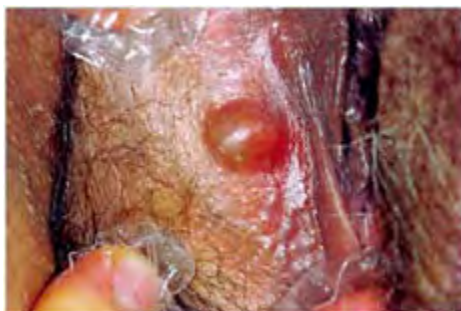**Figure 25.4** Bowen's disease (squamous cell carcinoma, intraepidermal). DLP ID: *squamous cell carcinoma in-situ 788*



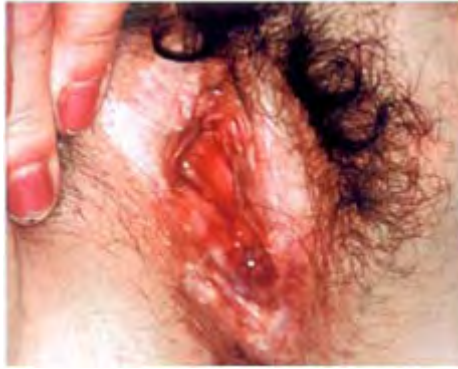**Figure 25.5** Candidosis. DLP ID: *candidiasis 296*



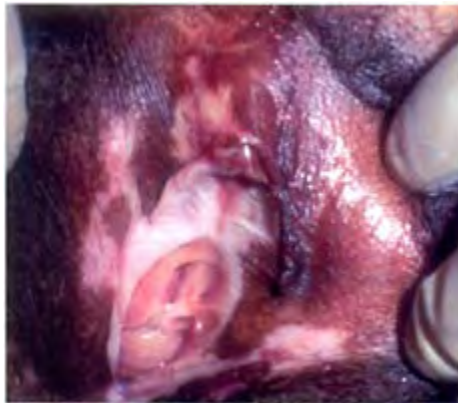**Figure 25.6** Herpes zoster. DLP ID: *herpes zoster virus infection 497*



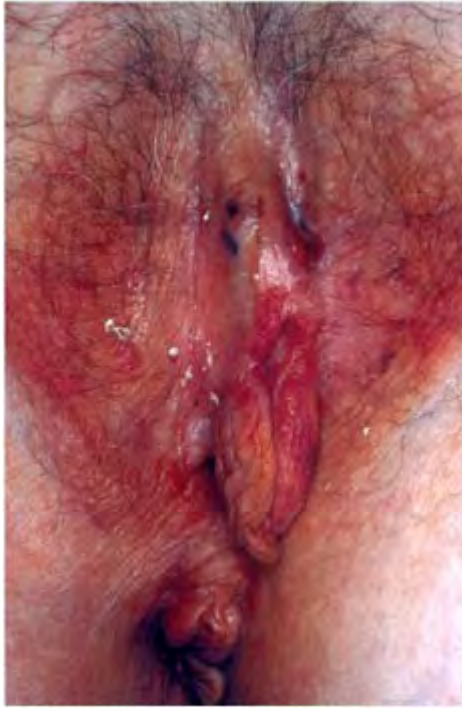**Figure 25.7** Hidradenoma papilliferum. DLP ID: *hidradenoma papilliferum 917*



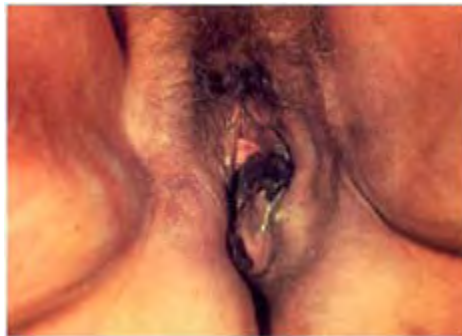**Figure 25.8** Lichen sclerosus et atrophicus. DLP ID: *lichen sclerosus* 2263



**Figure 25.9** Lichen sclerosus et atrophicus. DLP ID: *lichen sclerosus* 2263

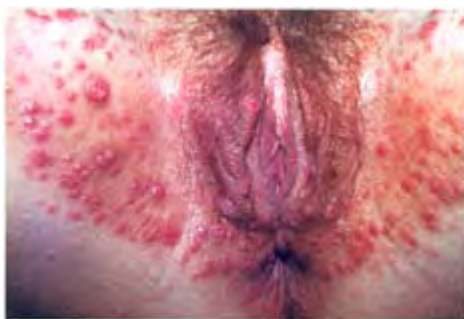

**Figure 25.10** Melanoma. DLP ID: *malignant melanoma 4758*

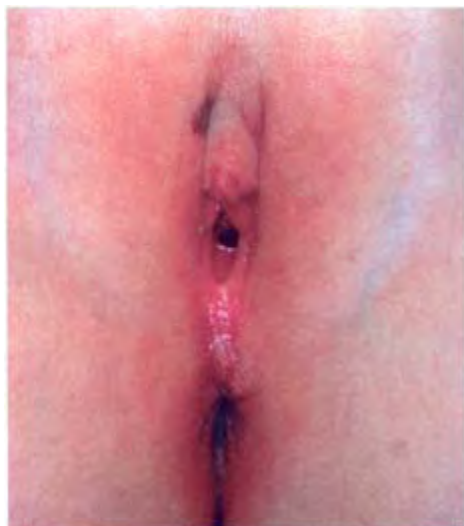

**Figure 25.11** Melanoma, level V with metastasis. DLP ID: *malignant melanoma 4758*. Courtesy of Dr B Fisher, Tel Aviv, Israel

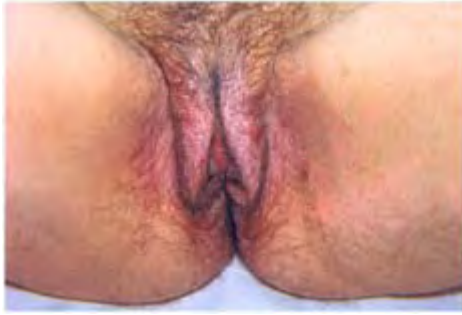



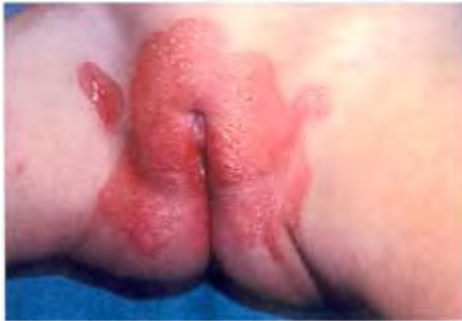**Figure 25.12** Molluscum contagiosum.  
DLP ID: *molluscum contagiosum 575*



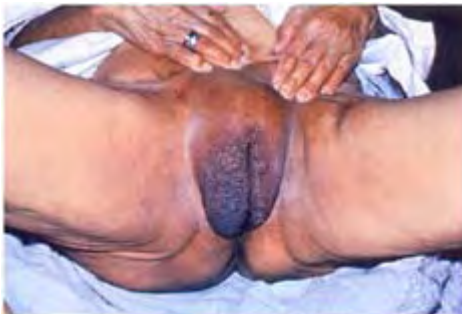**Figure 25.13** Nevus, junctional. DLP  
ID: *junctional nevus 1006*. Courtesy of  
Dr B Fisher, Tel Aviv, Israel



**Figure 25.14** Pruritus vulva. DLP ID: *pruritus vulvae 648*



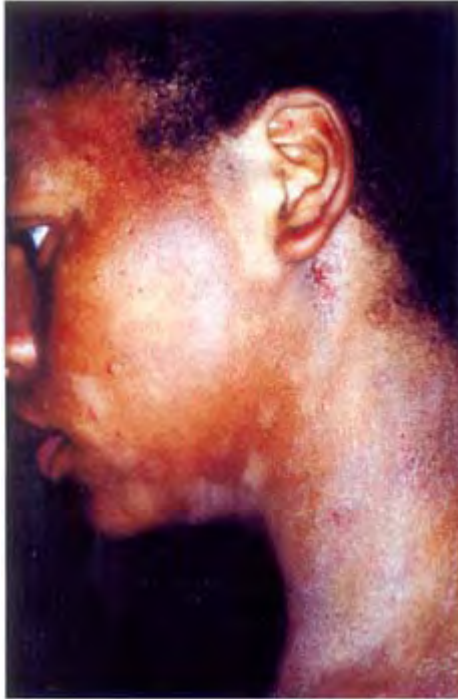**Figure 25.15** Psoriasis in versus. DLP ID: *inverse psoriasis 2083*. Courtesy of Dr B Fisher, Tel Aviv, Israel



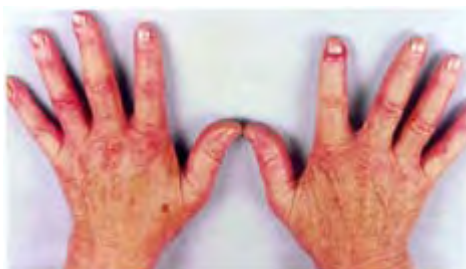**Figure 25.16** Scrofuloderma. DLP ID: *scrofuloderma 167*. Courtesy of Dr M Sollimon, Cairo, Egypt

# Diseases and conditions of pregnancy

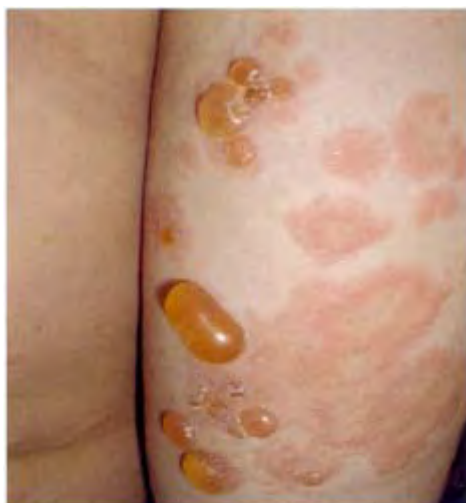## Pregnancy-related diseases and conditions



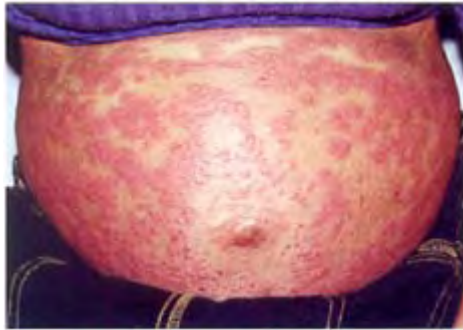
**Figure 26.1** Atopic dermatitis, exacerbated during pregnancy. Dermatology Lexicon Project (DLP) preferred term and number: DLP ID: *atopic dermatitis 2100*. Courtesy of Dr T Cestari, Porto Alegre, Brazil



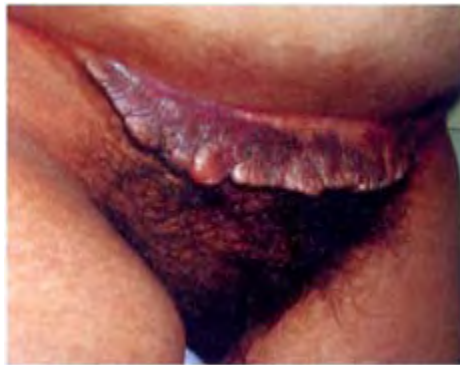**Figure 26.2** Dermatomyositis exacerbated during pregnancy. DLP ID: *dermatomyositis 1796*



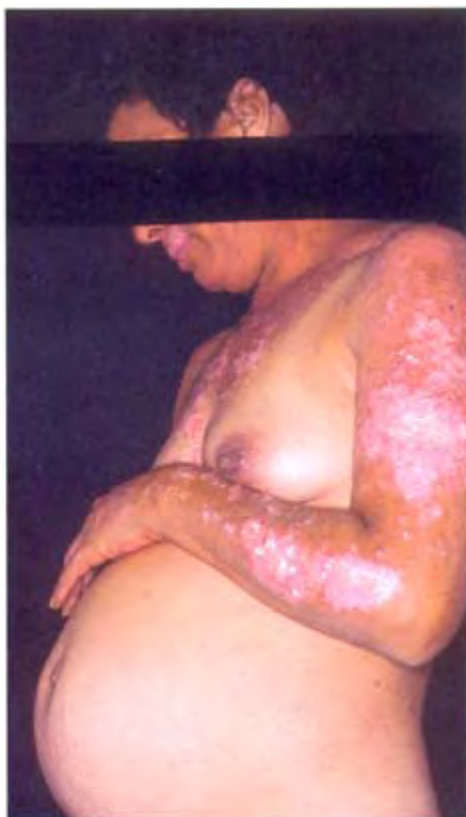**Figure 26.3** Herpes gestationis (pemphigoid gestationis). DLP ID: *herpes gestationis 1762*. Courtesy of Dr S Vassileva, Sofia, Bulgaria



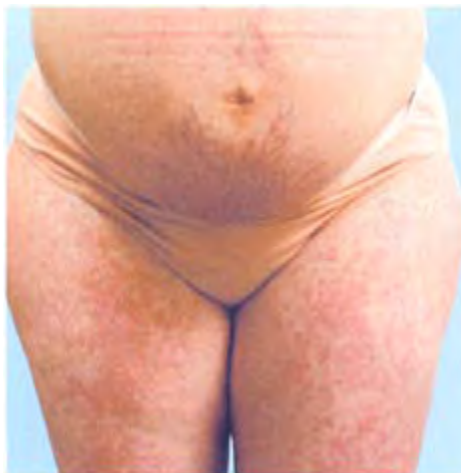**Figure 26.4** Herpes gestationis (pemphigoid gestationis). DLP ID: *herpes gestationis 1762*. Courtesy of Dr M Sollimon, Cairo, Egypt



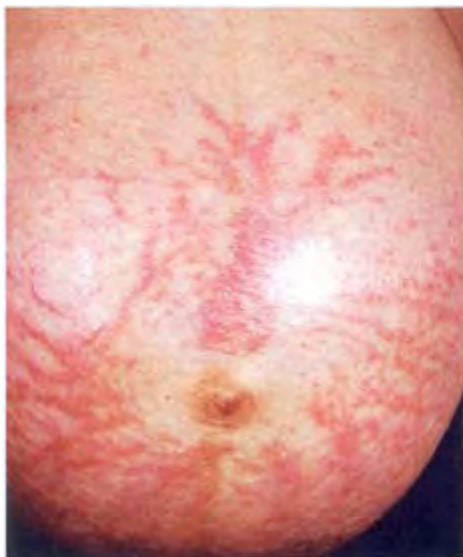
**Figure 26.5** Keloids following cesarian section. DLP ID: *keloid 1264*



**Figure 26.6** Lupus erythematosus, systemic, exacerbated during pregnancy DLP ID: *systemic lupus erythematosus 1808*. Courtesy of Dr T Cestari, Porto Alegre, Brazil

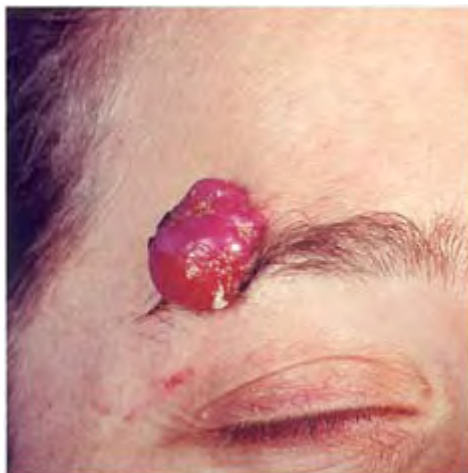


**Figure 26.7** Pruritic urticarial papules and plaques of pregnancy (PUPPP).  
DLP ID: *pruritic urticarial papules and plaques of pregnancy 2183*

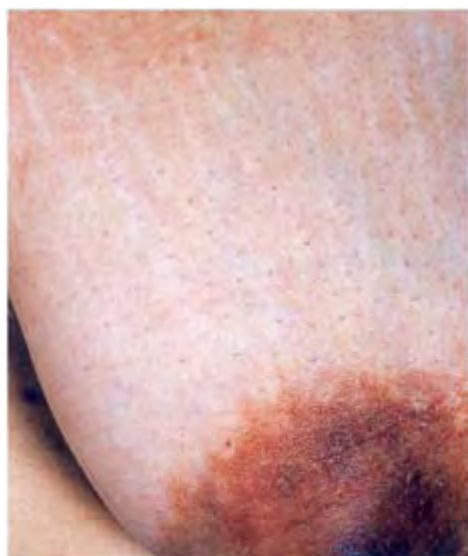

**Figure 26.8** Pruritic urticarial papules and plaques of pregnancy (PUPPP).  
DLP ID: *pruritic urticarial papules and plaques of pregnancy 2183*





**Figure 26.9** Pyogenic granuloma developing during pregnancy. DLP ID: *pyogenic granuloma 2823*



**Figure 26.10** Striae distensae. DLP ID: *striae distensae 5223*



# Index

- abscess, breast 107
- acanthosis nigricans 31, 68
- accessory nipple 107
- acne
  - aggravated by Vaseline 17
  - juvenile 8
  - steroid induced 17
- acne conglobata 17
- acne excoriee 18, 74
- acne keloidalis 18
- acrocephalosyndactyly 11
- acrodermatitis continua of Hallopeau 31
- acropustulosis, infantile 3
- actinic keratosis 57, 58
- acute generalized exanthematous pustulosis 71
- adenocarcinoma of the breast 63
- adenomatosis, erosive 107
- adult physical abuse 75
- AIDS 99–104
- ainhum 11
- allergic contact dermatitis 32, 33
- allergic reaction, drug induced 71, 72
- alopecia
  - due to hot combs 24
  - due to traction 24
  - permanent 24
  - systemic lupus erythematosus 25
- alopecia androgenic 23
- alopecia areata 20, 23
- alopecia totalis 24
- anetoderma 49
  - of prematurity 8
- angiolymphoid hyperplasia 58
- angioma 117
  - cherry 59
- anthrax 79
- Apert syndrome 11
- aphthous stomatitis 111
- apocrine glands, disorders of 17–19
- arthropod bite 95
- atopic dermatitis 8, 9, 32, 107, 123
- atrophoderma of Pasini and Pierini 49

- bacterial diseases 79–84
- basal cell carcinoma 63, 117
- basal cell nevus syndrome 63
- Behçet's disease 111, 117
- benign sebaceous gland tumor 61
- berloque dermatitis, due to cologne 42
- bite, human 75
- Bloch-Sulzberger syndrome 12
- blue nevus 60
- blueberry muffin syndrome 3
- borderline leprosy 82
- Bourneville's disease 14
- Bowen's disease 58, 118
- breast, diseases of 107–110
- bullosis diabetorum 45
- bullous diseases 44–48
- bullous impetigo 5
- burn, first-degree 3
  
- calcinosis cutis 49
- candidiasis 118
- candidosis 89, 108, 118
  - chronic mucocutaneous 115
- carcinoma, squamous cell 66, 67
- cat scratch disease 79
- chancroid 99
- cheilitis
  - actinic 111
  - drug induced 112
- cherry angioma 59
- chickenpox 88
- chondrodermatitis nodularis helices 49
- chromoblastomycosis 93
- chronic mucocutaneous candidiasis 115
- cicatrical pemphigoid 114
- clubbing of distal phalanges 20
- coccidiomycosis 93
- cold panniculitis 10
- comb alopecia 24
- condyloma acuminata 115
- congenital cytomegalovirus infection 3
- congenital nevus 116
- congenital syphilis 100
- connective tissue diseases 49–52
- contact dermatitis, due to
  - adhesive 32
  - cardioscope 3
  - celery 36
  - drug therapy 36
  - eye cream 32
  - hair dye 33

- nickel 33
- plant 33
- crusted scabies 97
- cryptococcosis 93, 102
- cutaneous anthrax 79
- cutaneous T cell lymphoma 66
- cutaneous tumors 57–67
- cutis laxa 11
- cutis marmorata 4
- cytomegalovirus infection 102
  - congenital 3
  
- Darier's disease 12
- decubitus ulcer, bullous 53
- delusion of parasitosis 76
- dental sinus 79
- dermatitis artefacta 76, 108, 109
- dermatitis herpetiformis 44
- dermatitis type subcorneal pustular IgA pemphigus 48
- dermatomyositis 50, 123
- dermatosis papulosa nigra 58
- desquamation, physiologic 4
- diabetic bulla 45
- diaper irritant dermatitis 9
- discoid lupus erythematosus 25
- dissecting cellulitis of the scalp 26
- drug eruption 71–73
  - exanthematous 71, 72
  - fixed 73
  - phototoxic 73
- dyshidrosis 18
- dyshidrotic dermatitis 18
- dysplastic nevus syndrome 59
  
- eccrine glands
  - disorders of 17–19
  - poroma 61
- ecthyma contagiosum 88
- elephantiasis verrucosa nostra 33
- eosinophilic folliculitis 102
- epidermoid cyst 60
- erosio interdigitalis blastomycetica candidiasis 89
- erysipelas
  - bullous 80
  - post-lumpectomy 108
- erythema ab igne 40
- erythema elevatum diutinum 33
- erythema induratum 102
- erythema multiforme 103
  - like drug eruption 73
  - minor 73

- erythema nodosum 34, 68
- erythema toxicum 4
- exanthematous drug eruption 71, 72
- exanthematous pustulosis, acute generalized 71
- exfoliative dermatitis 34
- exfoliative erythroderma 34
  
- factitial dermatitis 74, 75, 108
- familial atypical mole-melanoma syndrome 59
- Favre-Rachouchot syndrome 58
- first-degree burn 3
- fixed drug eruption 73, 103
- focal dermal hypoplasia 4, 5, 12
- folliculitis, due to waxing 80
- Fox-Fordyce disease 18
- fungal diseases 89–94
- furuncle 80
  
- genital herpes simplex 103
- genodermatoses 11–14
- girls, young, diseases of 8–10
- glomangioma 20
- Goltz syndrome 12
- Goltz-Gorlin syndrome 4, 5
- gout 68
- Graham-Little syndrome 25
- granuloma annulare 34
- granuloma inguinale 99
- granulomatous rosacea 83
  
- Hailey-Hailey disease 45, 116
- hair, disorders of 23–27
- halo nevus 60
- hand, foot, and mouth disease 112
- hemangioma 117
- hereditary diseases
  - hemorrhagic telangiectasia 113
  - infants and children 1–14
- herpes gestationis 123, 124
- herpes progenitalis 103
- herpes simplex 5
  - labialis 86
- herpes zoster 86, 87, 118
  - with keloid formation 87
- hidradenitis suppurativa 19
- hidradenoma papilliferum 118
- histiocytosis 9
- histoplasmosis 103
- hypergammaglobulinemia 69
- hyperpigmentation
  - drug induced 42

- post-inflammatory 41
- hyperthyroidism goiter 69
- hypomelanosis of Ito 12
- hypopigmented mycosis fungoides 66
- hypoplastic breast 108
- hypothyroidism 69
  
- idiopathic clubbing of fingers 20
- immunosuppression-related Kaposi's sarcoma 104
- impetigo
  - bullous 5
  - non-bullous 80
- incontinentia pigmenti achromians 12
- infantile acne 8
- infantile benign cephalic pustulosis 7
- insect bite reaction 95
- irritant contact dermatitis 3
- Ito, hypomelanosis of 12
  
- Jacquet's erosive diaper dermatitis 9
- junctional nevus 120
- juvenile xanthogranuloma 10
  
- Kaposi's sarcoma 64, 104
- keloid 59, 109, 124
- keratinous cyst, infected 60
- keratoacanthoma 64
- keratosis follicularis 12
- keratosis pilaris 34
  
- larva migrans 95
- leishmaniasis, cutaneous American 96
- leprosy
  - borderline 82
  - lepomatous 82
  - tuberculoid 83
- lichen amyloidosis 35
- lichen planopilaris 25
- lichen planus 35, 112
- lichen sclerosus 119
- linear bullous dermatosis 45
- lingua nigra 113
- lipoid proteinosis 35
- livedo reticularis 54
- lobomycosis 93
- lupus erythematosus
  - discoid 25, 50
  - neonatal 5
  - systemic 25, 50, 51, 124
- lupus milaris disseminatus faciei 83

- lupus vulgaris 83
- Lyme borreliosis 88
- Lyme disease 81
- lymphangioma circumscriptum 60
  
- Majocchi's granuloma 90
- malignant melanoma 119
- mastitis, acute 6
- median nail dystrophy 75
- melanoma 119
  - amelanotic 65
    - level 1 65
    - level 2 65
    - level 4 65
- melanonychia, benign, longitudinal 20
- melanonychia striata 20
  - in AIDS patient 104
- melasma 40
- Melkersson-Rosenthal syndrome 113
- Merkel cell carcinoma 66
- metastatic breast adenocarcinoma 63
- milia, neonatal 6
- molluscum contagiosum 88, 120
- morphea 52
- Mucha-Habermann disease 37
- mucocele 113
- mutilating palmoplantar keratoderma 13
- mycetoma 94
- mycobacterial diseases 79–84
- mycosis fungoides
  - erythrodermic 66
  - hypopigmented 66
- myiasis 96
  
- nail, disorders of 20–22
  - dystrophy, median 75
  - pigment, drug induced 21
- necribosis lipoidica diabetorum 69
- necrosis, due to contact 6
- necrotizing vasculitis 56
- neonatal cephalic pustulosis 7
- neonatal lupus erythematosus 5
- neurodermatitis 36
- neurofibromatosis 13
- neurotic excoriations 76, 109
- nevus
  - blue of Jadassohn 60
  - congenital 116
  - halo of Sutton 60
  - junctional 120
  - sebaceous 61



- woolly hair 26
- nevus spilus 10
- nevus unis lateralis 61
- New World leishmaniasis 96
- newborns, diseases of 3–7
- nickel dermatitis 33
- non-hereditary diseases of skin structure 15–27
- normal vulva 6
- nummular dermatitis 36
  
- Olmstead syndrome 13
- onychomycosis 21
- ophiasis 26
- oral lesions 111–114
- orf 88
- orolabial herpes simplex 86, 112
- Osier-Weber-Rendu syndrome 113
  
- pachyonychia congenita 21
- Paget's disease 109
  - extramammary 116
- panniculitis, due to cold injury 10
- papulonecrotic tuberculid 84
- papulosquamous diseases 31–39
- paracoccidioidomycosis 94
- parasitic diseases 95–98
- parasitophobia 76
- paronychia candidiasis 21
- pediculosis capitis 96
- pellagra 36
- pemphigoid
  - bullous 46
  - cicatricial 113
- pemphigus, benign familial 46
  - chronic 116
- pemphigus erythematous 46
- pemphigus foliaceus 46, 114
- pemphigus herpetiformis 47
- pemphigus vulgaris 47, 48, 114
- perianal diseases 115–116
- perifolliculitis capitis abscedens et suffodiens 26
- perineal diseases 115–116
- perioral dermatitis 19
- Peutz-Jeghers syndrome 114
- photoallergic reaction, drug induced 36
- photocontact dermatitis, due to
  - celery 36
  - drug 36
- phototoxic drug eruption 73
- phototoxic reaction, drug induced 73
- physical abuse, adult 75

- phytophotodermatitis 36
- picker's nail 75
- piebaldism 41
- pigment changes, diseases of 40–43
- pigmentation, drug induced 21
- pigmented contact dermatitis 42
- pityriasis lichenoides et varioliformis acuta 37
- pityriasis rosea 37
- pityriasis rubra pilaris 37
- poikiloderma of Civatte 41
- pomade acne 17
- poroma, eccrine 61
- porphyria cutanea tarda 69
- post-inflammatory hyperpigmentation 41,42
- pregnancy-related diseases 123–125
- primary syphilis 100
- pruritic urticarial papules and plaques of pregnancy 125
- pruritus vulva 120
- pseudoblastomycosis interdigitale 89
- pseudoepitheliomatous hyperplasia 114
- pseudomonas nail infection 21
- pseudopelade of Brocq 26
- pseudoxanthoma elasticum 13, 52
- psoriasis 10, 37–39
- psoriasis inversus 120
- psoriatic nails 22
- psychodermatology 74–76
- pterygium 22
- pustulosis, due to *Malassezia furfur* 7
- pyoderma
  - gangrenosum 54
  - secondary to scabies 81
  - secondary to stasis ulcer 82
- pyogenic granuloma 61, 114, 125
  
- Ramsay Hunt syndrome 87
- reticulohistiocytosis, multicentric 70
- rhus dermatitis 33
- rickettsial diseases 85
- Riehl's melanosis 42
- Rocky Mountain spotted fever 85
- rodent ulcer of basal cell carcinoma 63
- rosacea 19
  
- sarcoidosis 22, 70
- scabies 7, 97
  - crusted 97
  - elderly patient 97
  - pyoderma 81
- scalded skin syndrome 7
- scalp, diseases of 23–27

- scleroderma 52
  - scrofuloderma 84, 120
  - sebaceous glands
    - disorders of 17–19
    - hyperplasia of 7
  - seborrheic dermatitis 39
  - seborrheic keratosis 57, 62, 110
  - secondary syphilis 100, 101
  - Senear Usher syndrome 46
  - sexually transmitted disease 99–104
  - sickle cell leg ulcer 55
  - skin structure, diseases of 15–27
  - smallpox 88
  - spider bite 98
  - sporotrichosis 94
  - squamous cell carcinoma 58, 66, 67
    - intraepidermal 118
  - staphylococcal scalded skin syndrome 7
  - stasis dermatitis 55
  - stasis ulcer 55
    - pyoderma 82
  - steatocytoma multiplex 62
  - steroid induced acne 17
  - striae, due to steroids 110
  - striae distensae 125
  - subcorneal pustulosis 48
  - supernumerary nipple 107
  - syphilis
    - congenital 100
    - primary 100
    - secondary 100, 101
    - tertiary 101
  - syringoma, chondroid 62
  - systemic diseases, cutaneous manifestations of 57–67
  - systemic lupus erythematosus 25
- 
- tertiary syphilis 101
  - tick bite 98
  - tinea capitis 90
    - due to *Microsporum canis* 27
    - with kerion formation 90
  - tinea corporis 90, 91
  - tinea cruris 91
  - tinea faciei 91
  - tinea incognito 91
  - tinea nigra 92
  - tinea pedis 92
  - tinea versicolor 92
  - toxic erythema 4
  - trachyonychia 22
  - traction alopecia 24

- tricholemmoma 62
- trichothiodystrophy 27
- trichotillomania 76
- tuberous sclerosis 14
- typhus, due to *Rickettsia conorii* 85
  
- ulceration of skin, necrosis 6
- Urbach-Wiethe syndrome 35
  
- varicella 88
- varicosities 56
- variola 88
- vascular diseases 53–56
- vasculitis, necrotizing 56
- verruca vulgaris 88
- vesicular diseases 44–48
- viral diseases 86–88
- vitiligo 43, 110
- Von Recklinghausen syndrome 13
- vulva
  - diseases of 117–120
  - normal 6
  
- Waldenstrom macroglobulinemia 69
- woolly hair nevus 26
  
- xanthelasma 70
- xanthogranuloma, juvenile 10